

In Search of Gold Standard Treatment of Hemorrhoid

Dr. Tania Ahmed

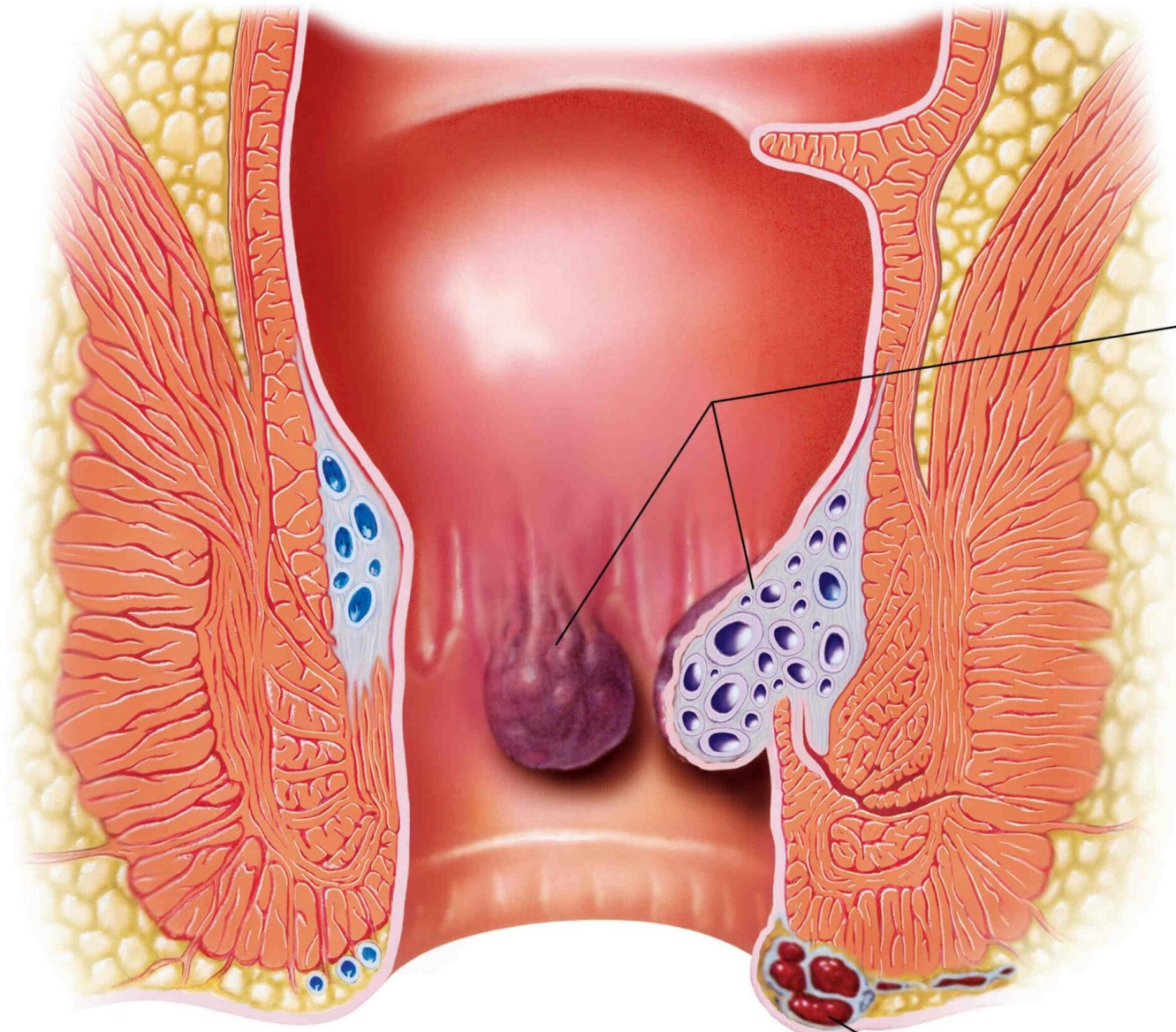
Assistant Professor,

Department of Surgery,

Ad-Din Women's Medical College Hospital, Maghbazar, Dhaka.

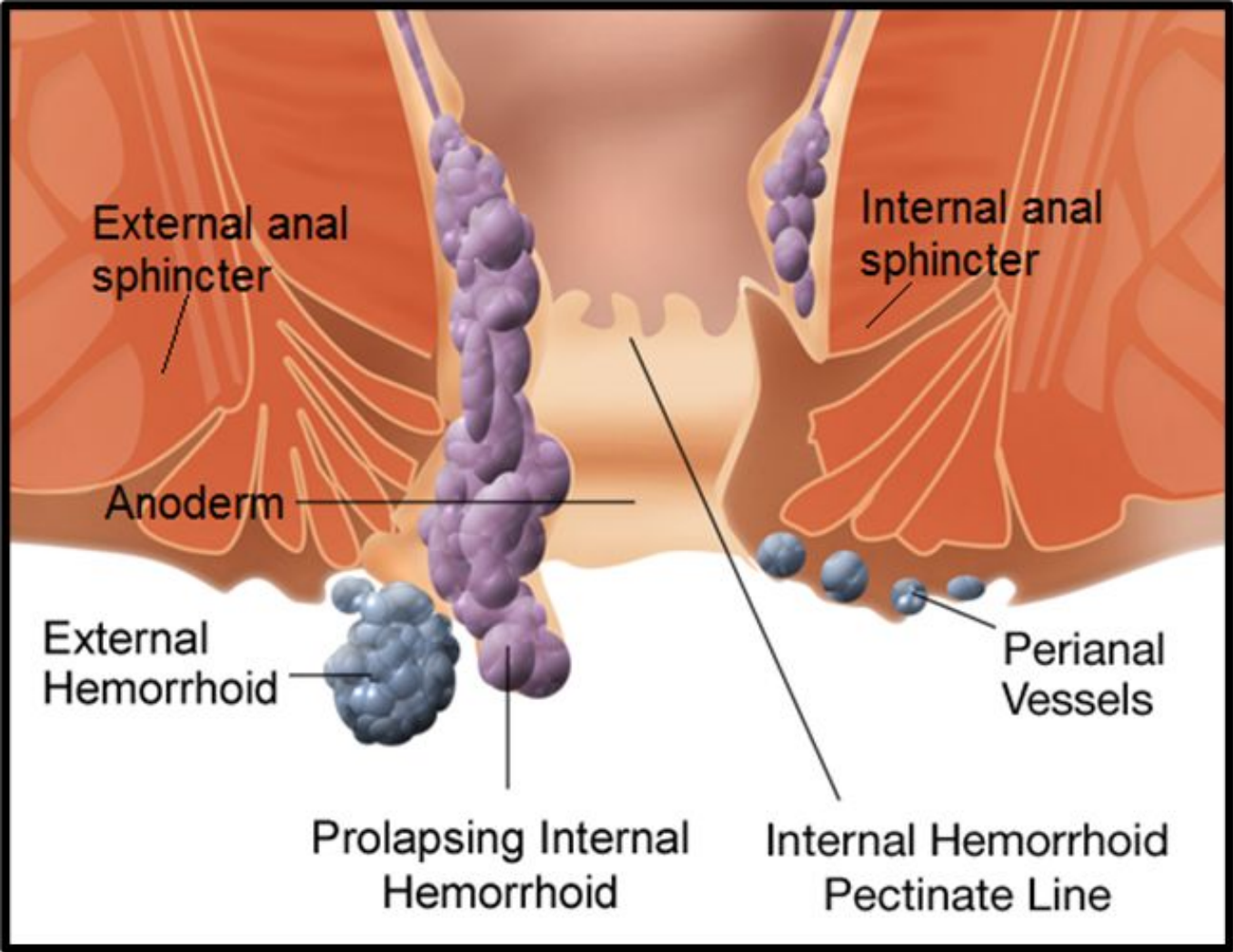
Definition Of Hemorrhoid

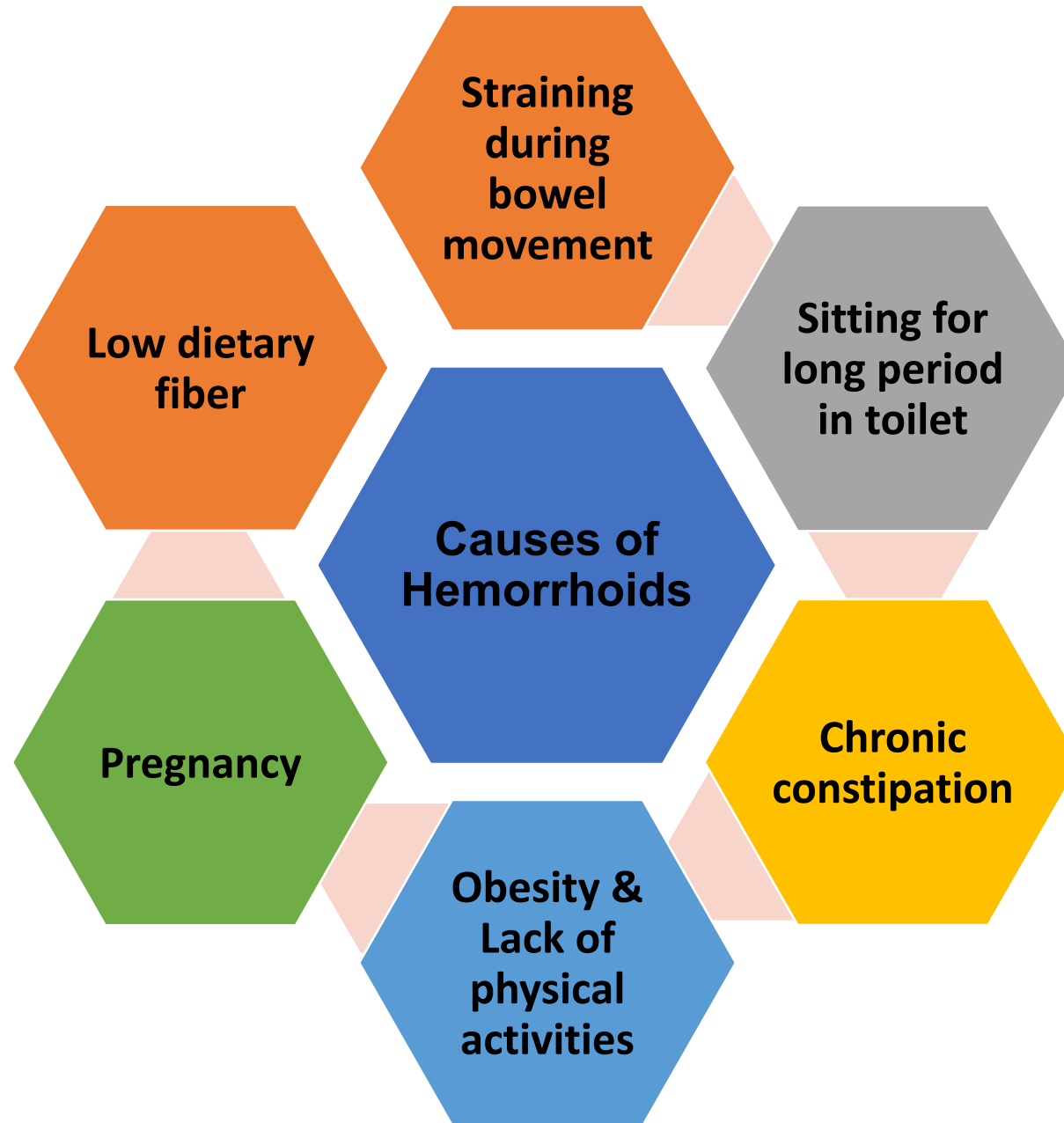
- ❑ Dilated veins of the anal canal



**Internal
Hemorrhoids**

**External
Hemorrhoids**

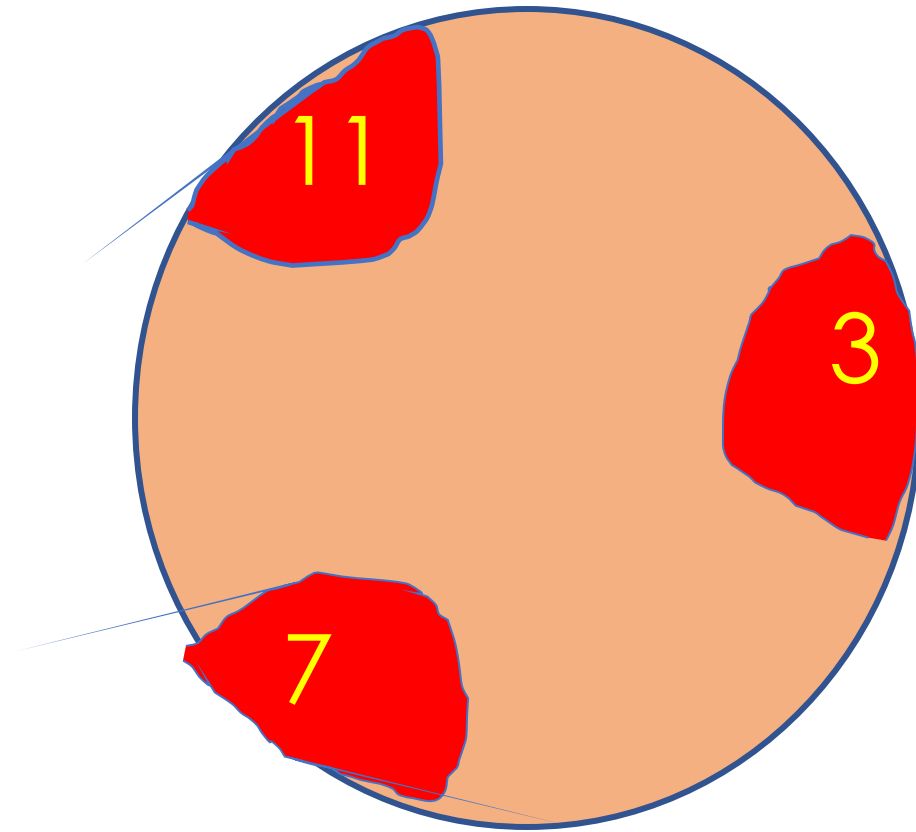
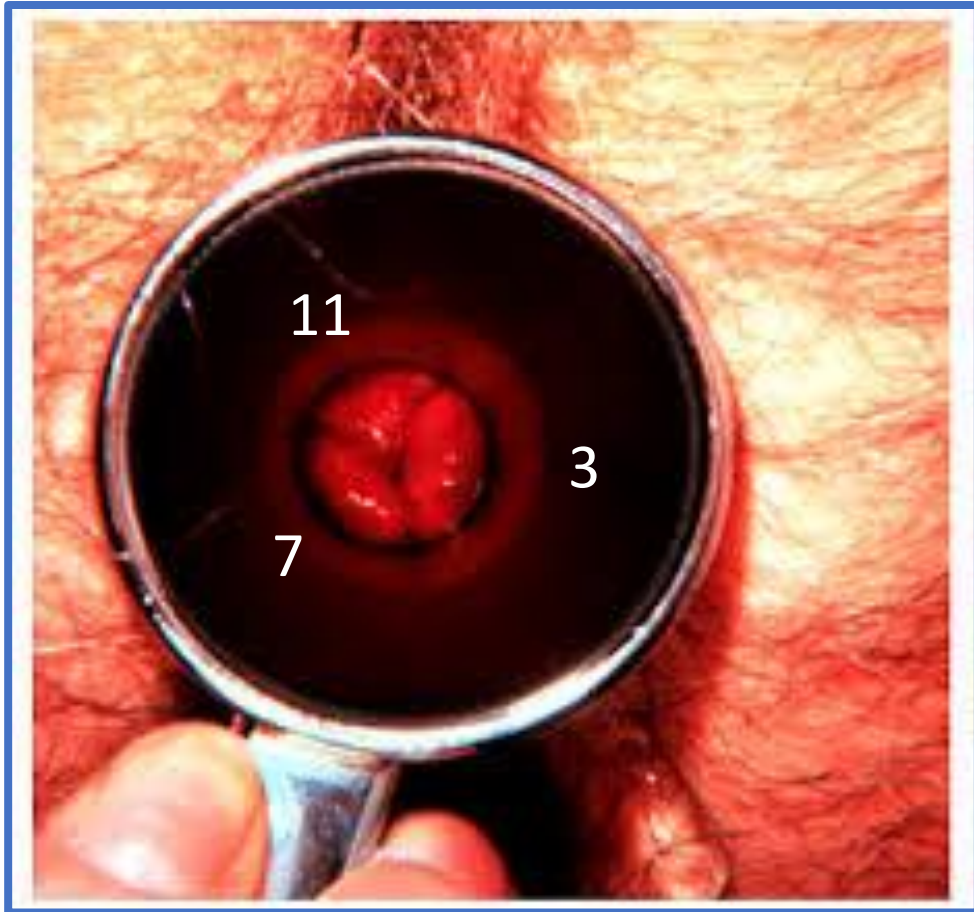


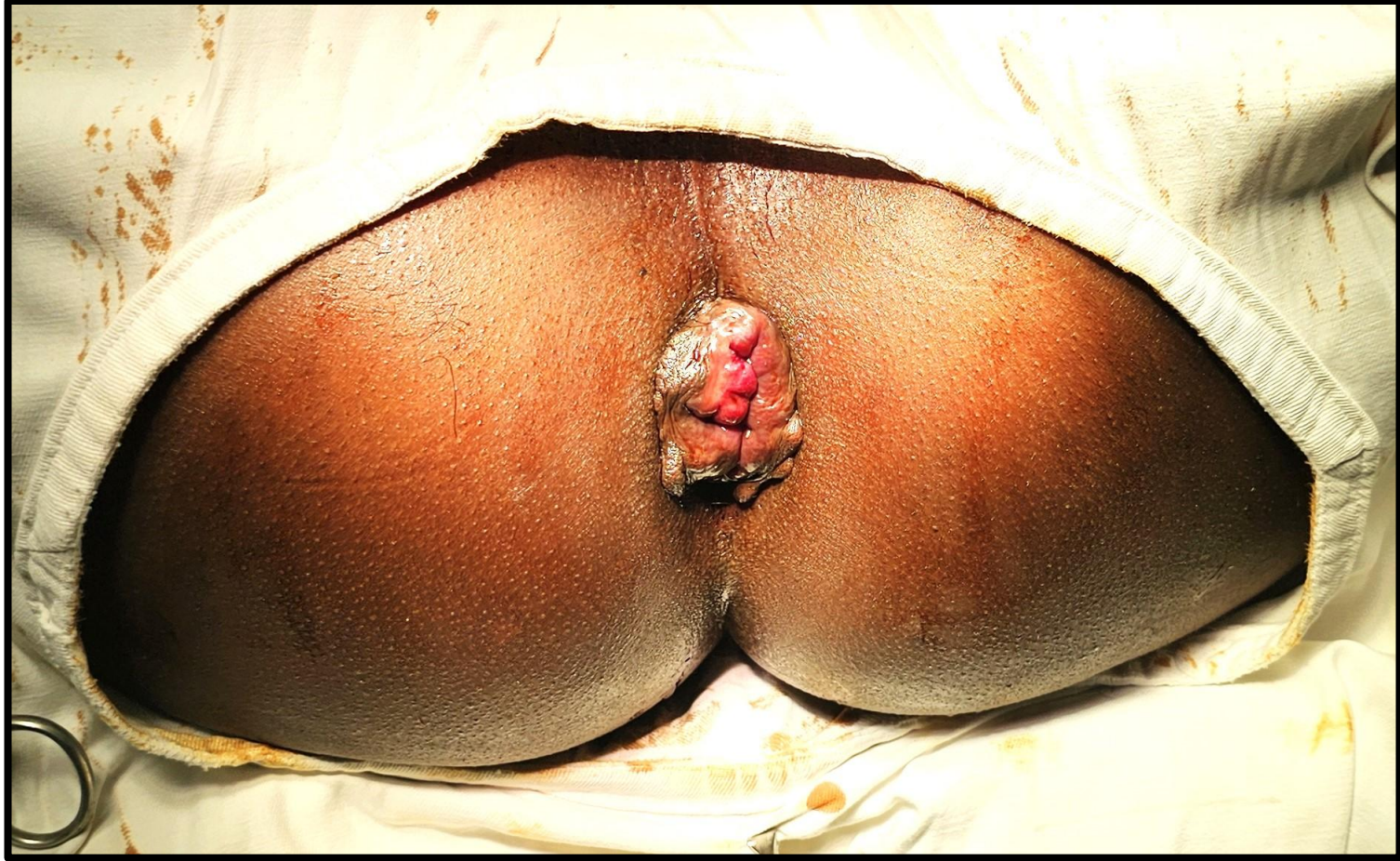
Classification of hemorrhoid

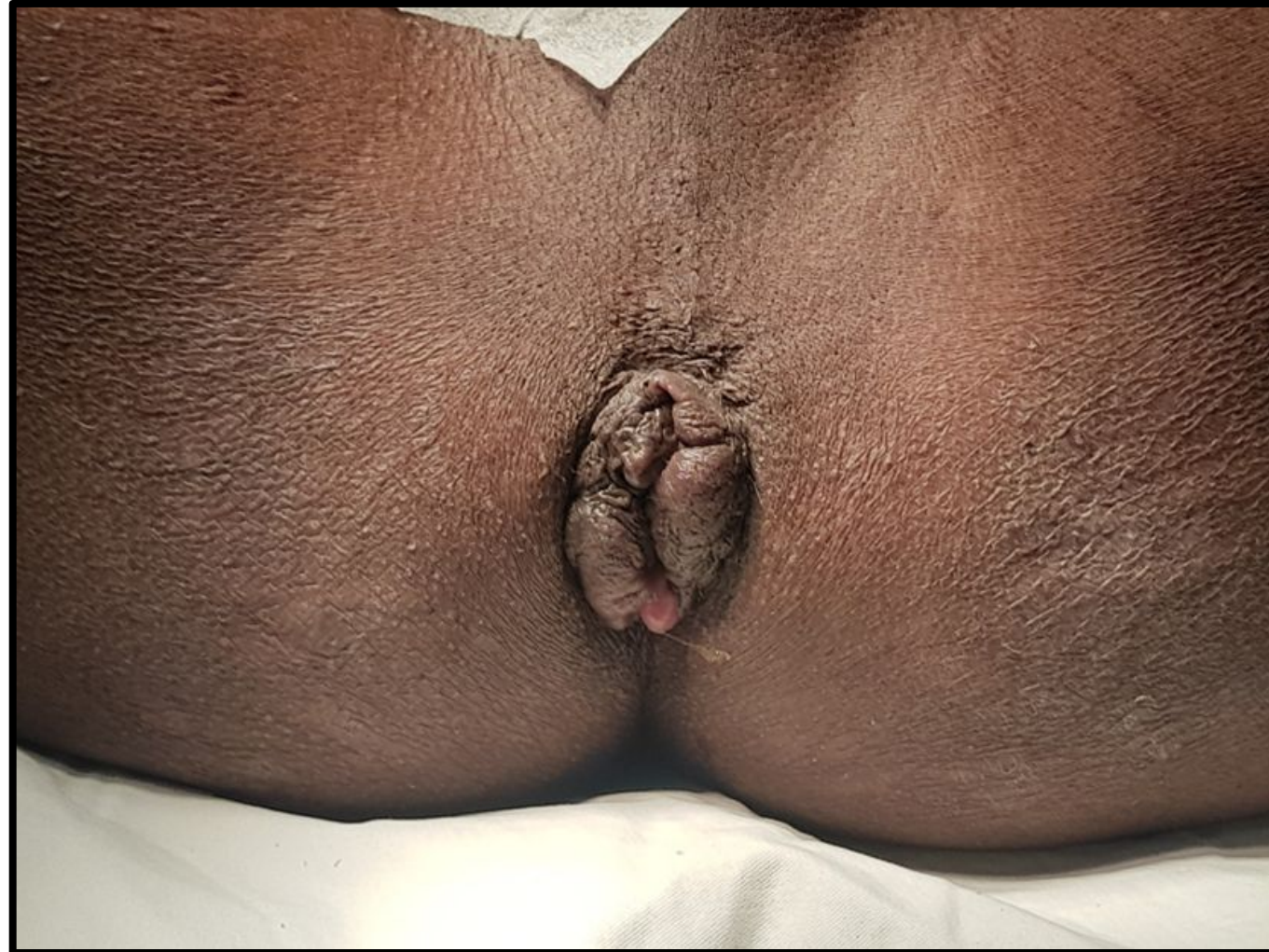- 1st degree-bleeds only-no prolapse
- 2nd degree-Prolapsed but reduces spontaneously
- 3rd degree-prolapsed but needs manual reduction
- 4th degree-permanently prolapsed

3, 7 and 11 o'clock position of hemorrhoid on proctoscopy





4th degree piles



Treatment

□ Conservative-Stool softener, life style modifications, venoconstricting agent etc.

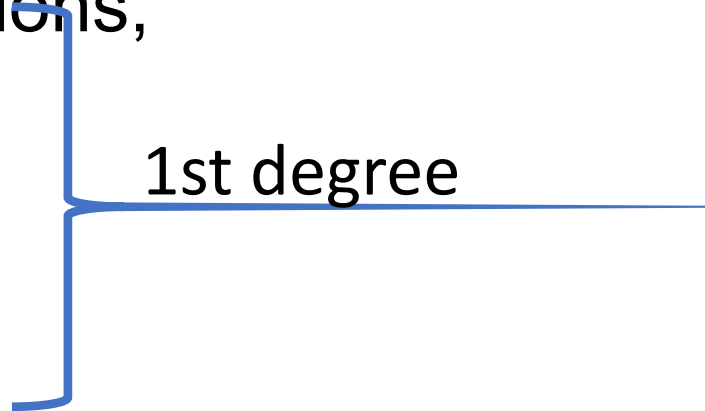
□ Injection Sclerotherapy

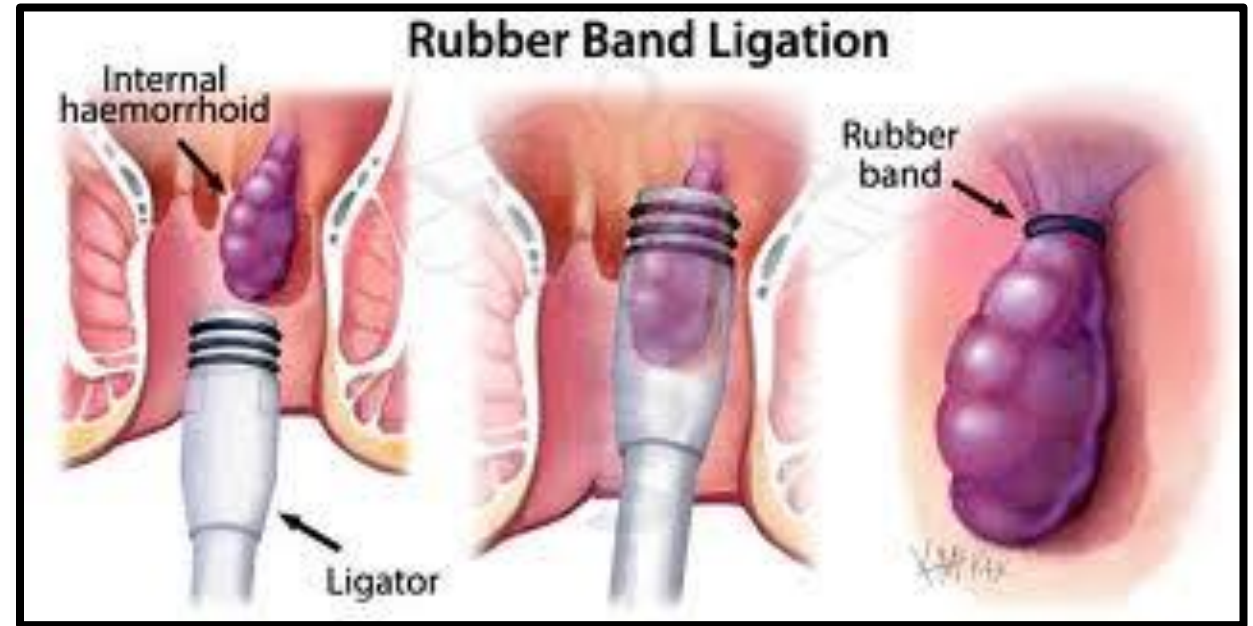
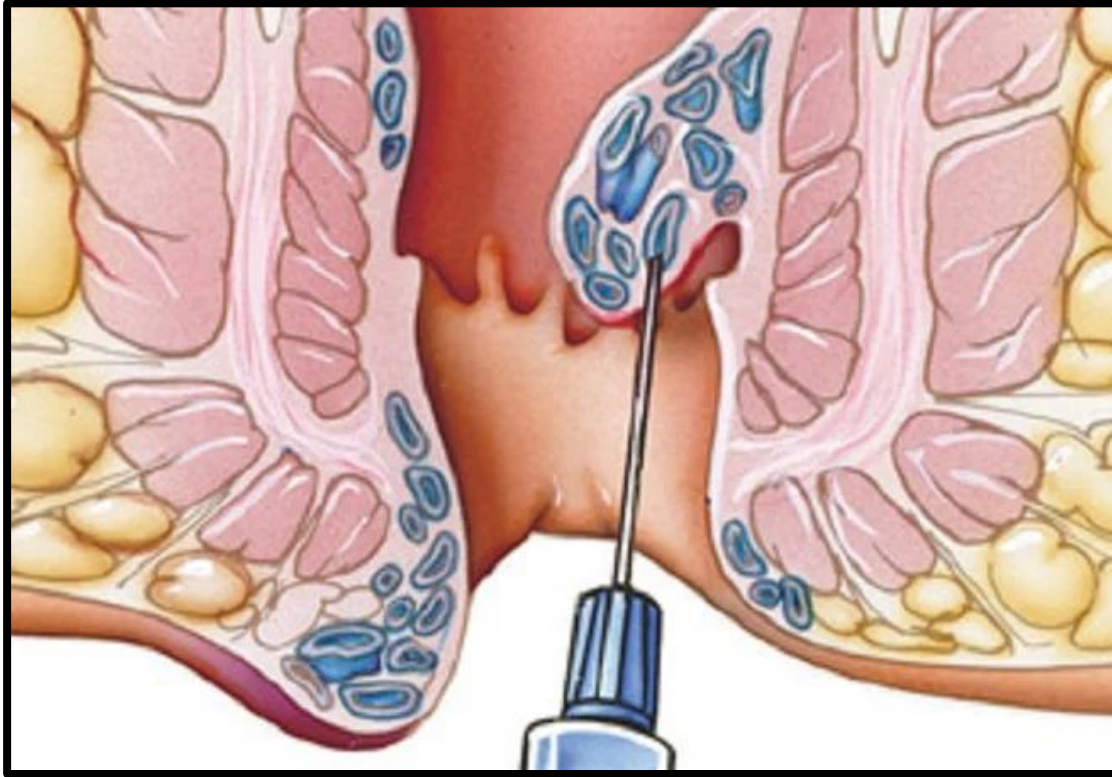
□ Infra-red coagulation

1st degree

□ Band ligation

2nd degree

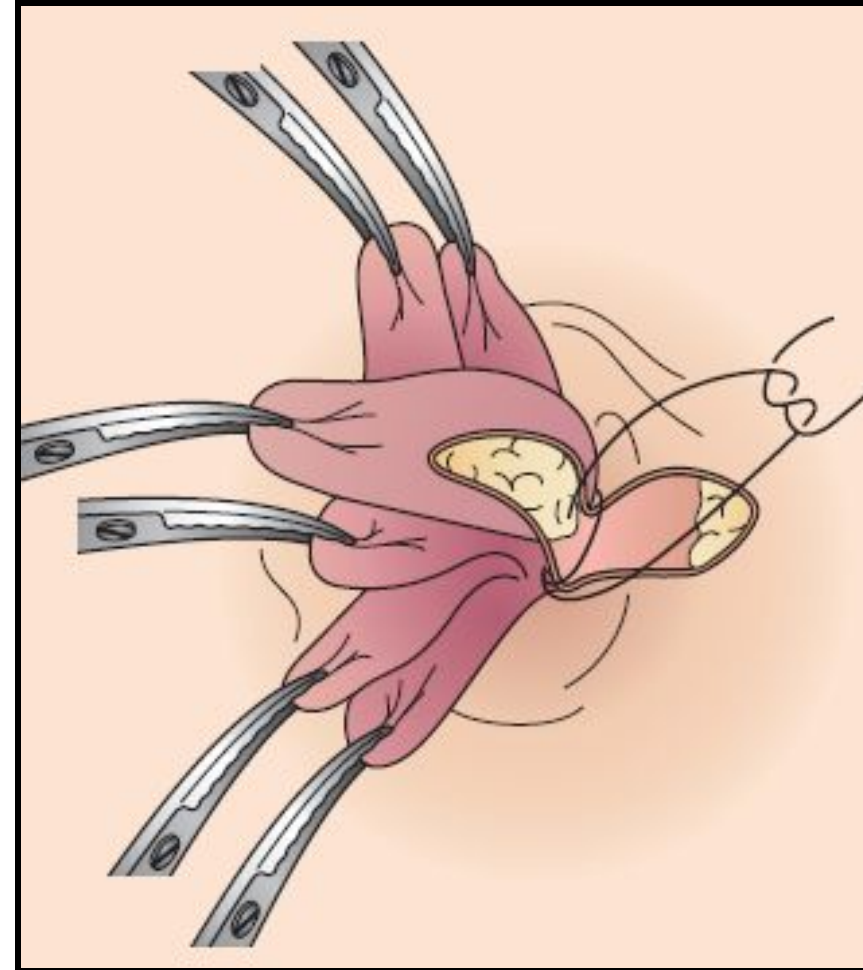
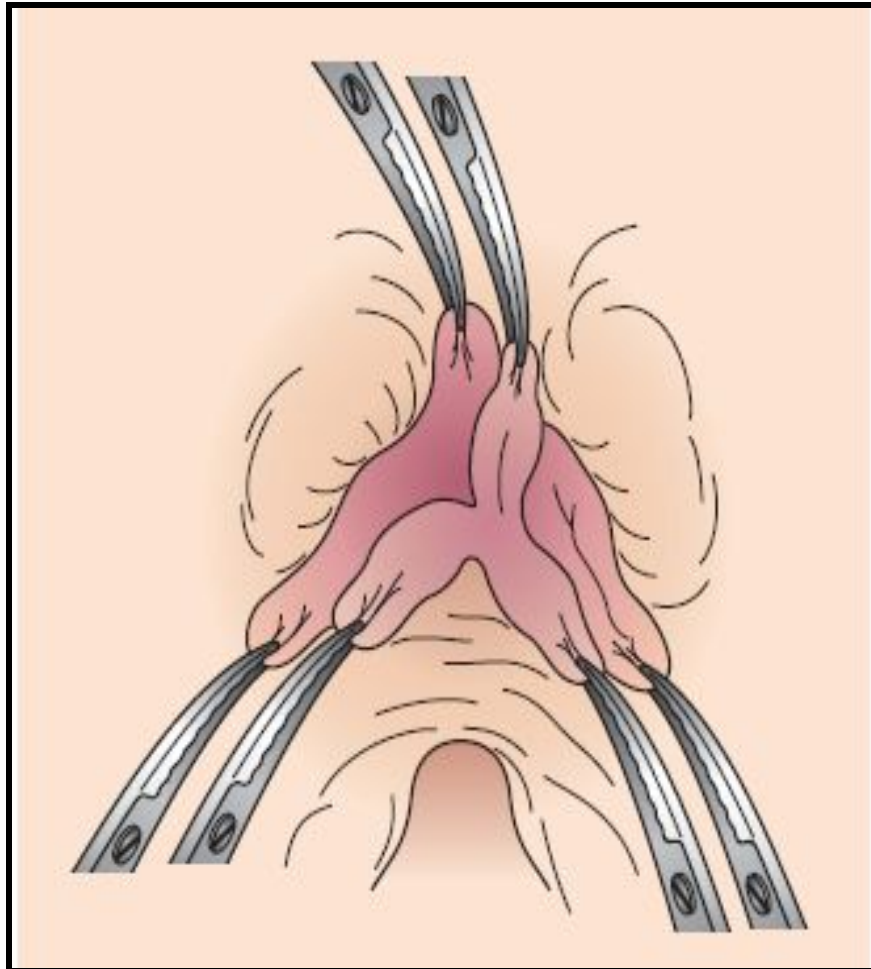




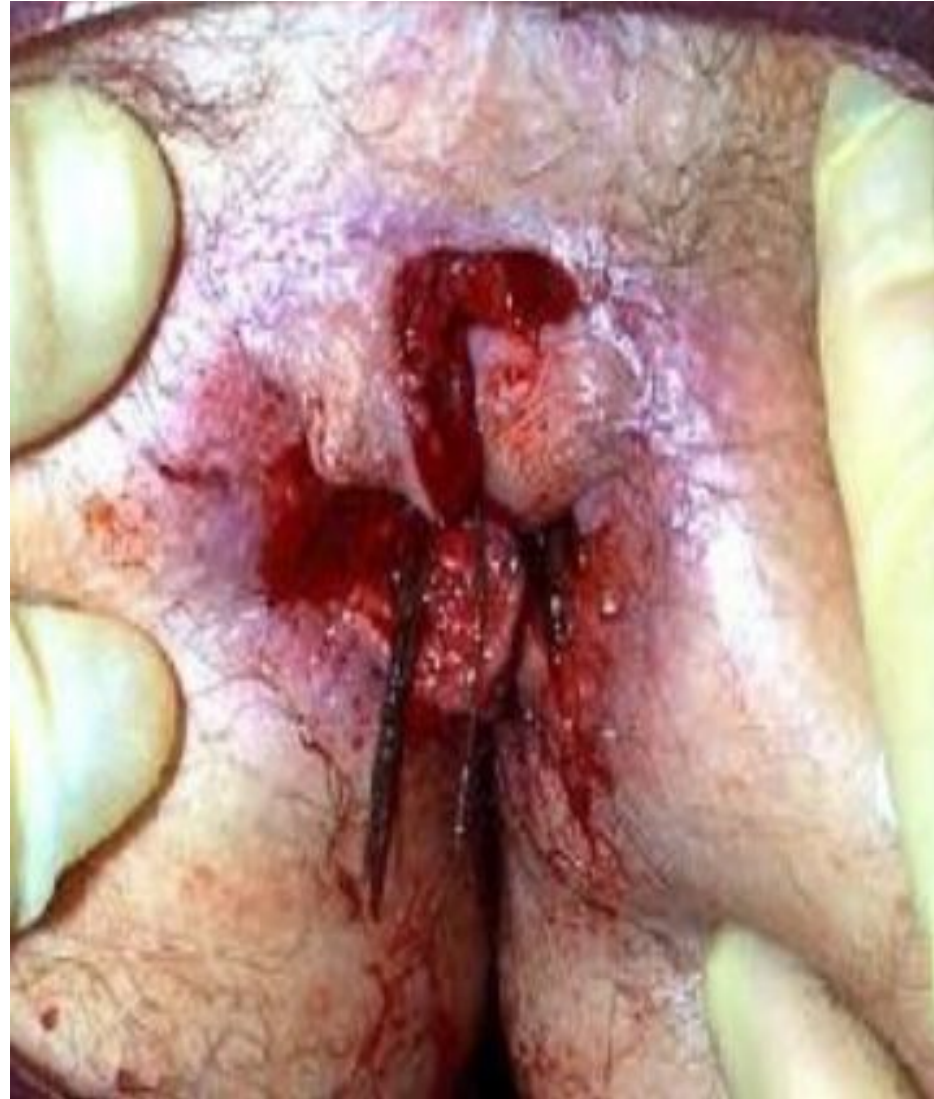For 1st to 4th degree

- Open Hemorrhoidectomy(Milligan Morgan Operation)
- Stapled hemorrhoidopexy
- Laser hemorrhoidectomy
- HAL(Doppler guided Hemorrhoidal artery ligation)

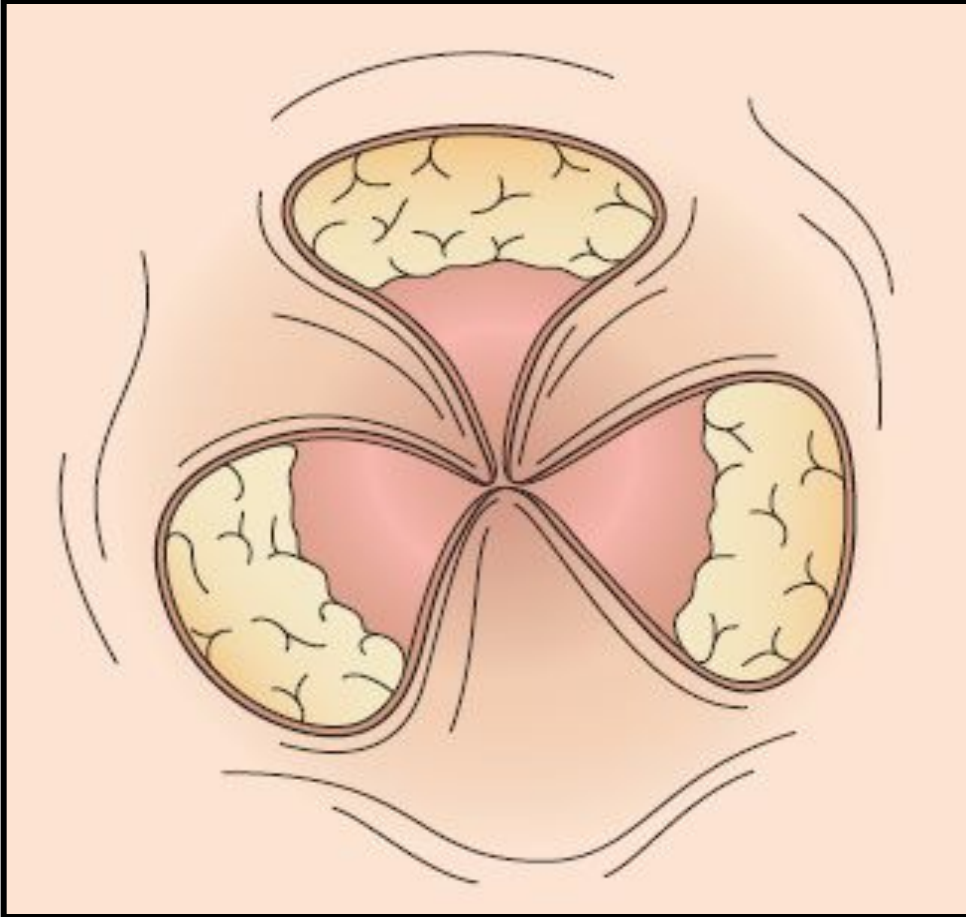
Steps of Milligan Morgan Hemorrhoidectomy



Postoperative wound after Milligan Morgan



Post Hemorrhoidectomy Appearance



Disadvantages

- Healing takes 6-8 weeks
- Pain
- Reactionary hemorrhage
- Wound infection
- Anal stenosis
- Anal incontinence

Principles of Longo Operation

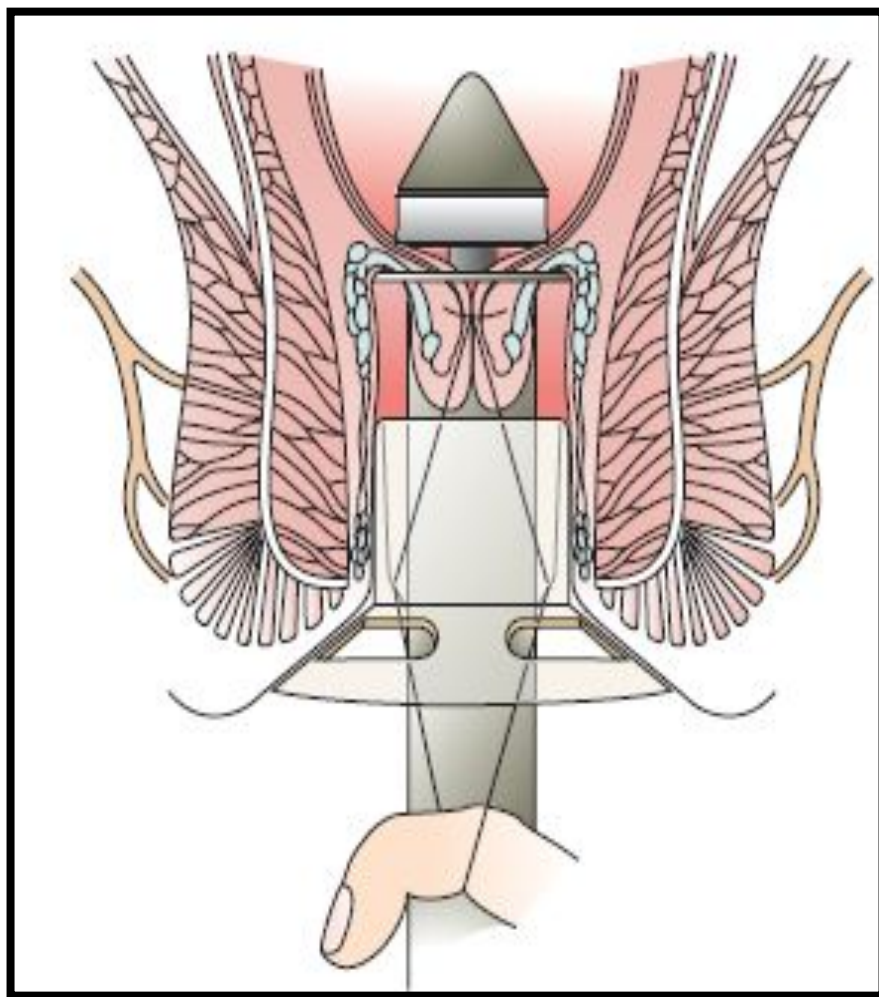
Professor Antonio Longo first described Stapled hemorrhoidopexy in 1998

- Hemorrhoid pedicles are not excised
- Operation is done 2 cm above the dentate line
- A segment of anorectal mucosa and submucosa is excised and stapled by a circular stapler
- Hence no bleeding, no open wound
- Hemorrhoid pedicles are lifted off
- Blood supply to hemorrhoids are cut off
- Hemorrhoid shrinks

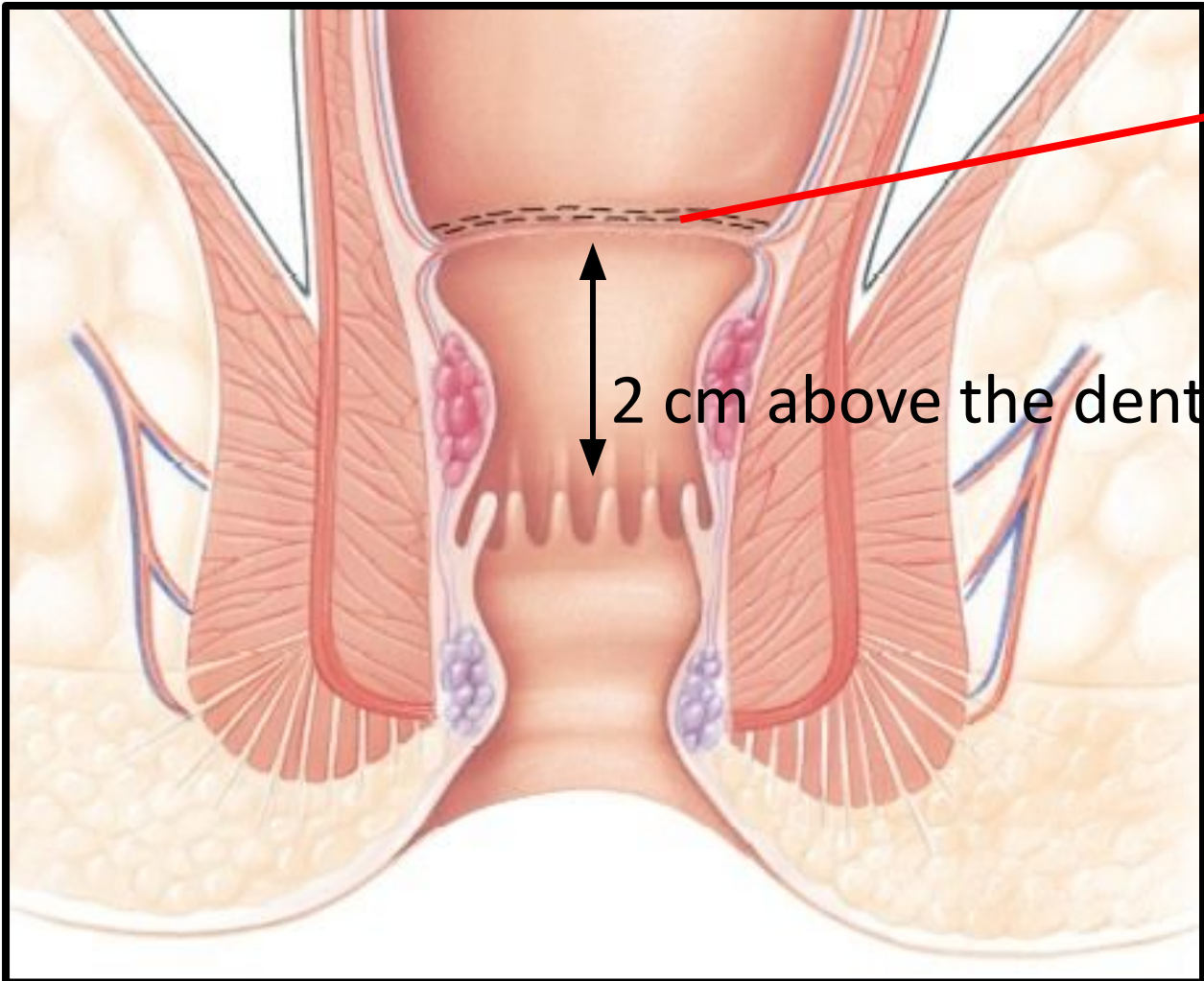
Stapler gun(34mm) for Longo operation



Stapler for Longo operation




Stapled Hemorrhoidopexy



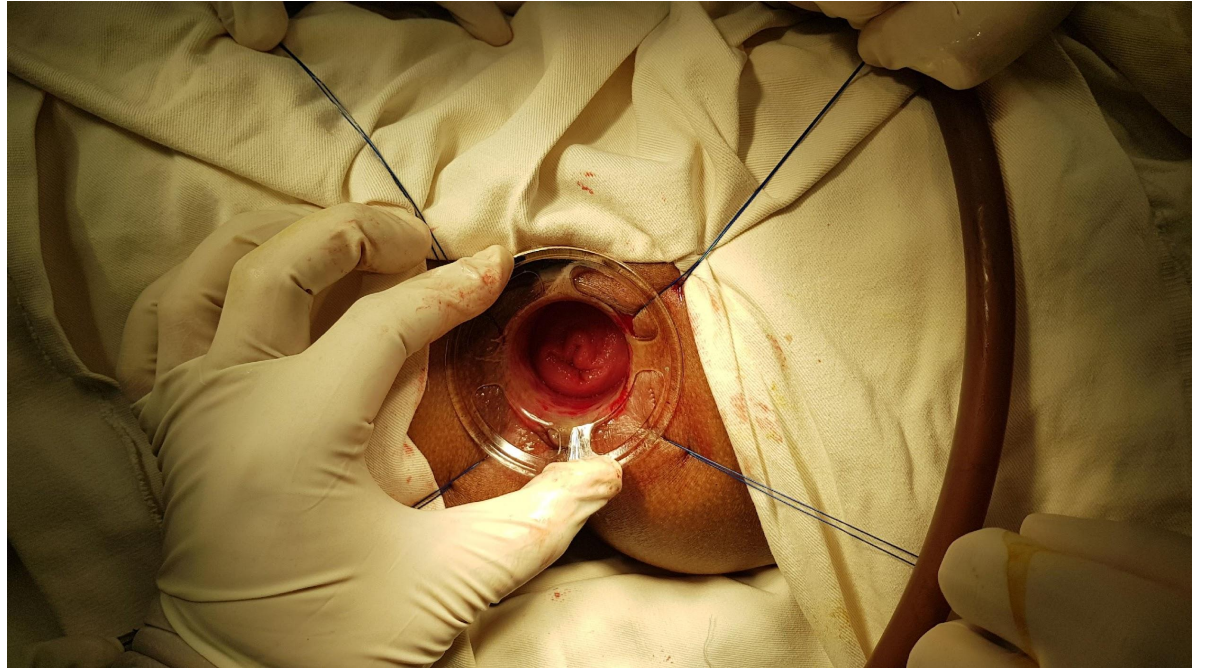
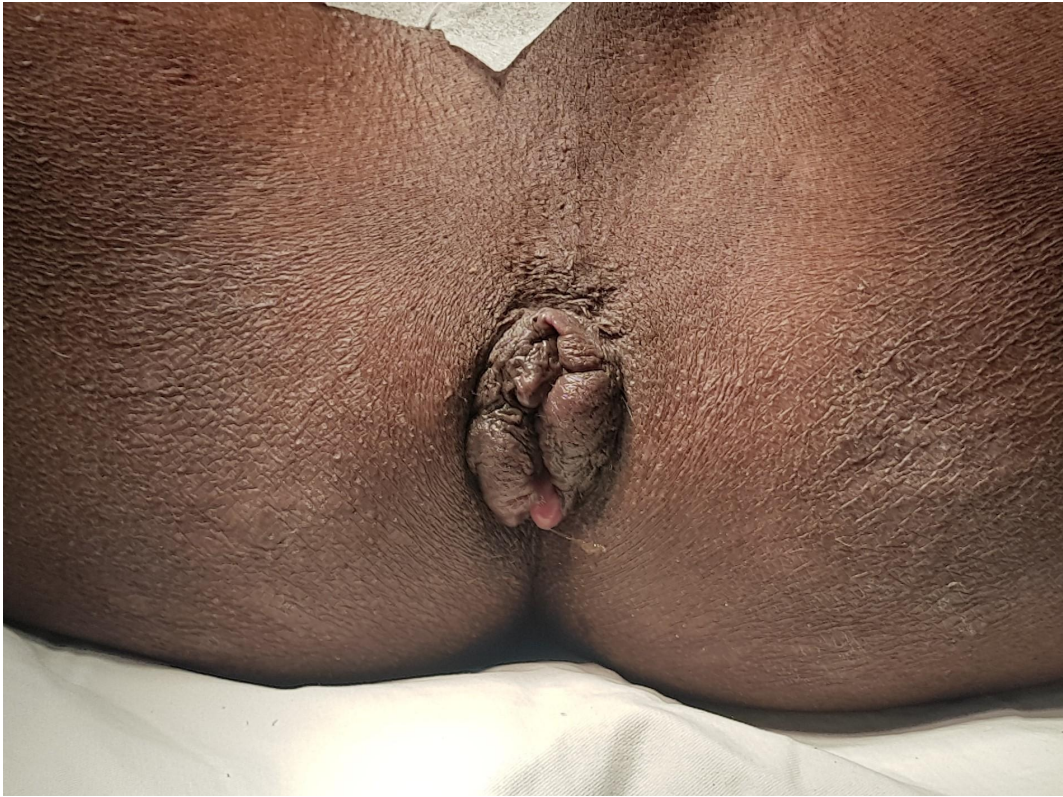Stapler line

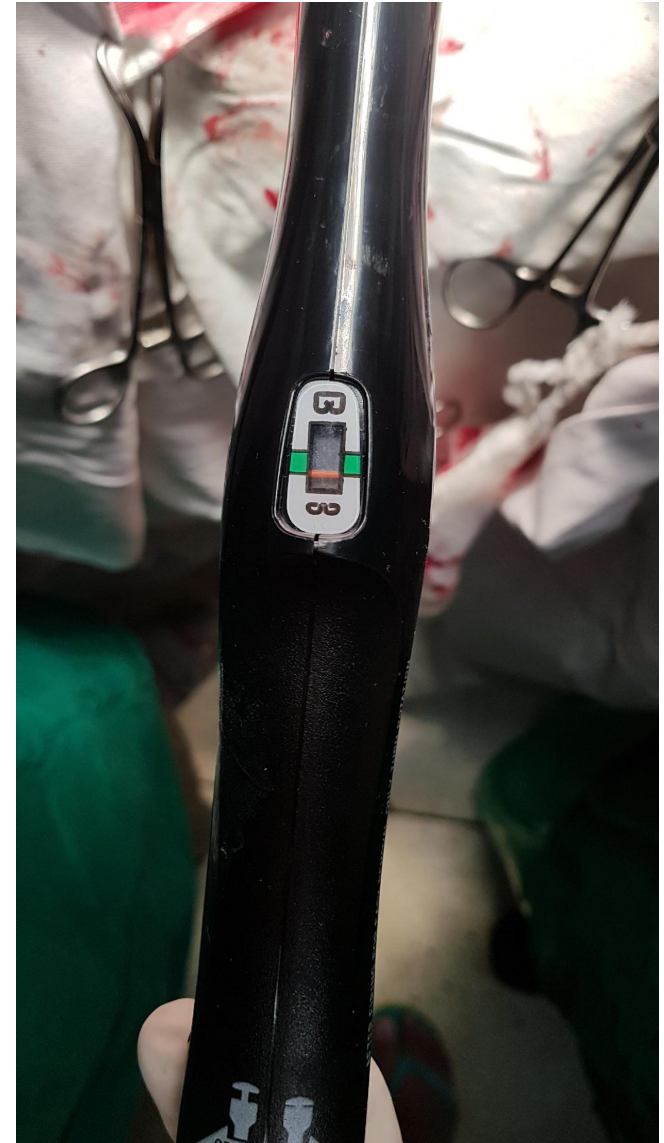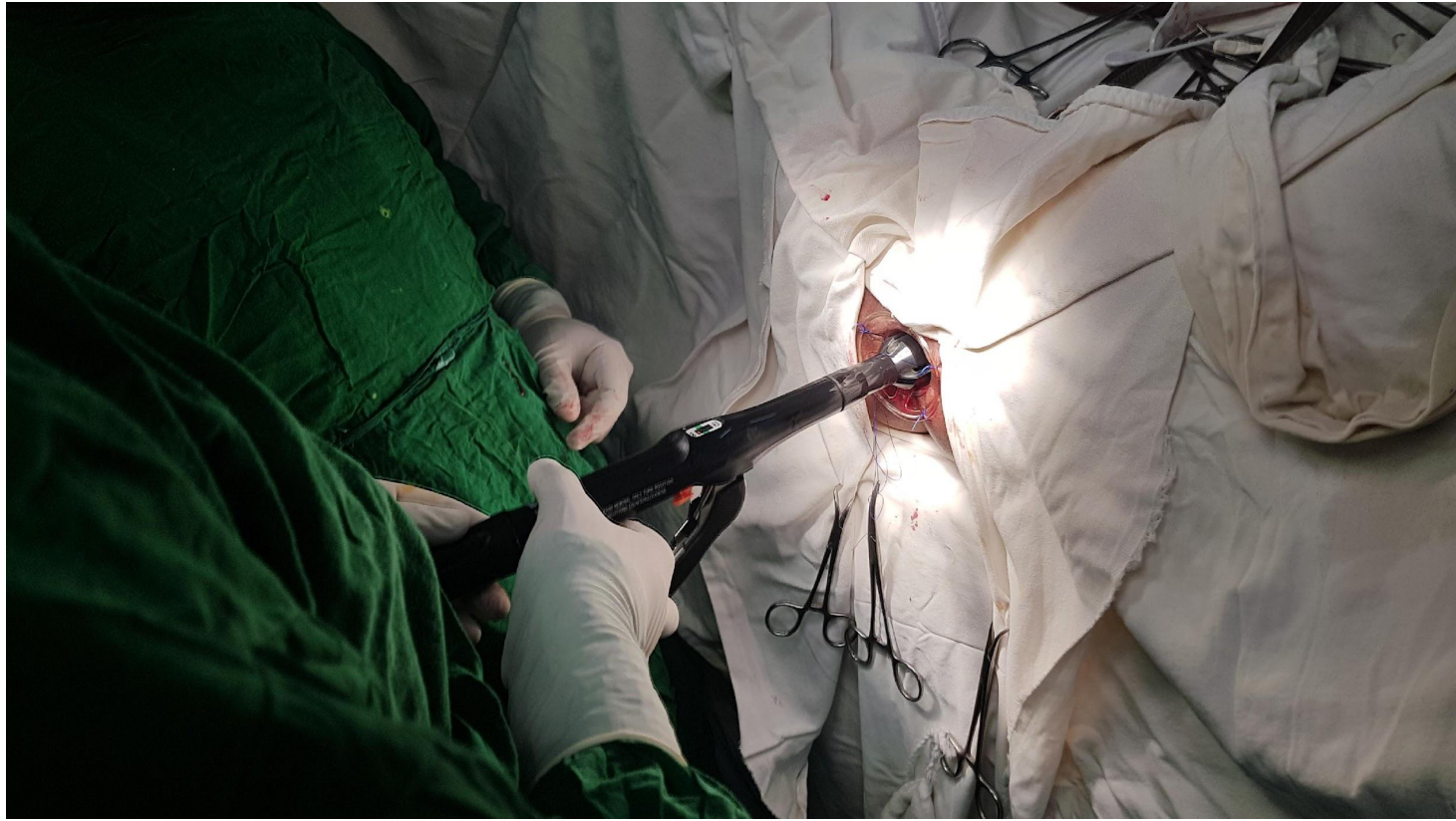2 cm above the dentate line



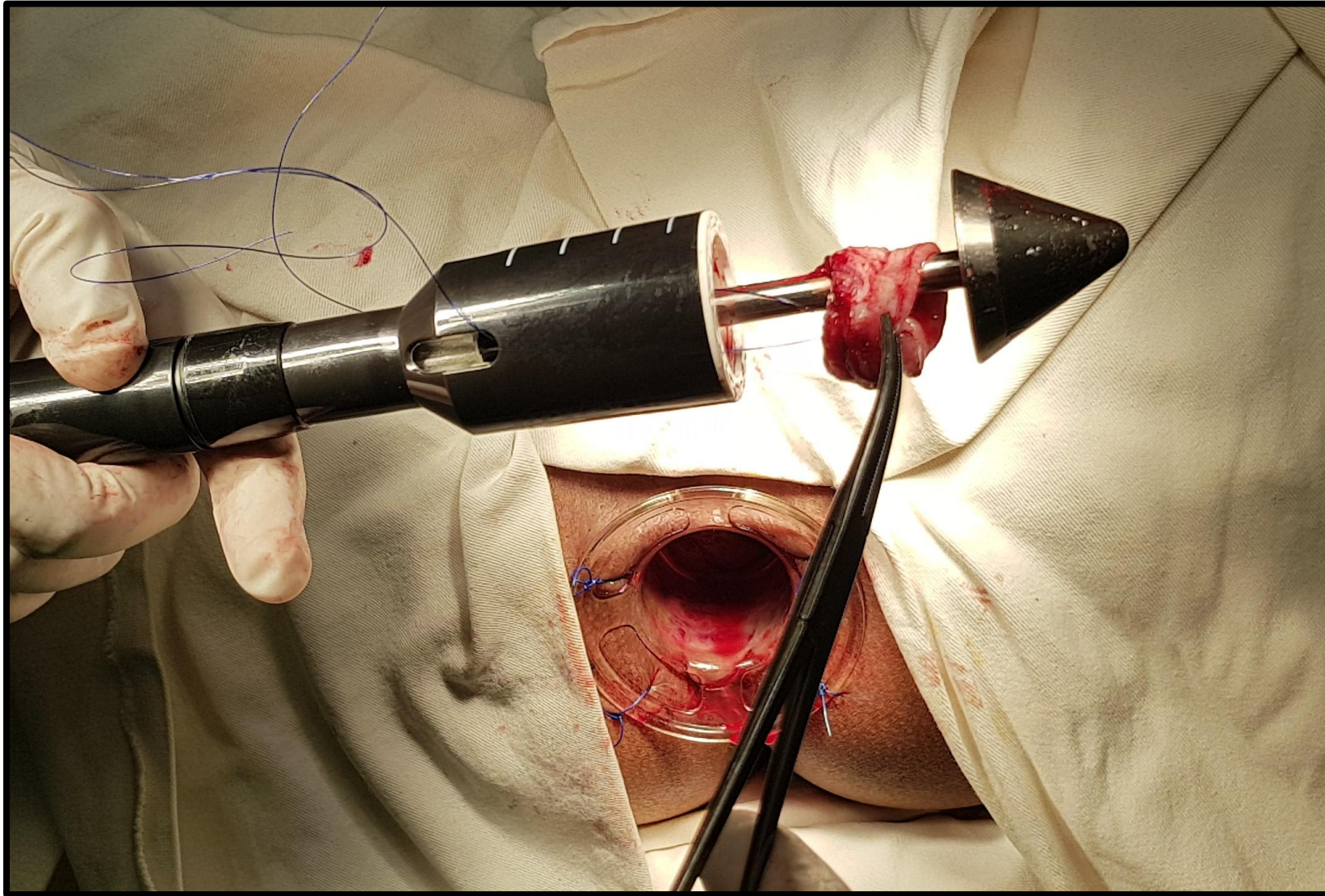
In 1998, Italian surgeon Antonio Longo described the Stapled hemorrhoidopexy



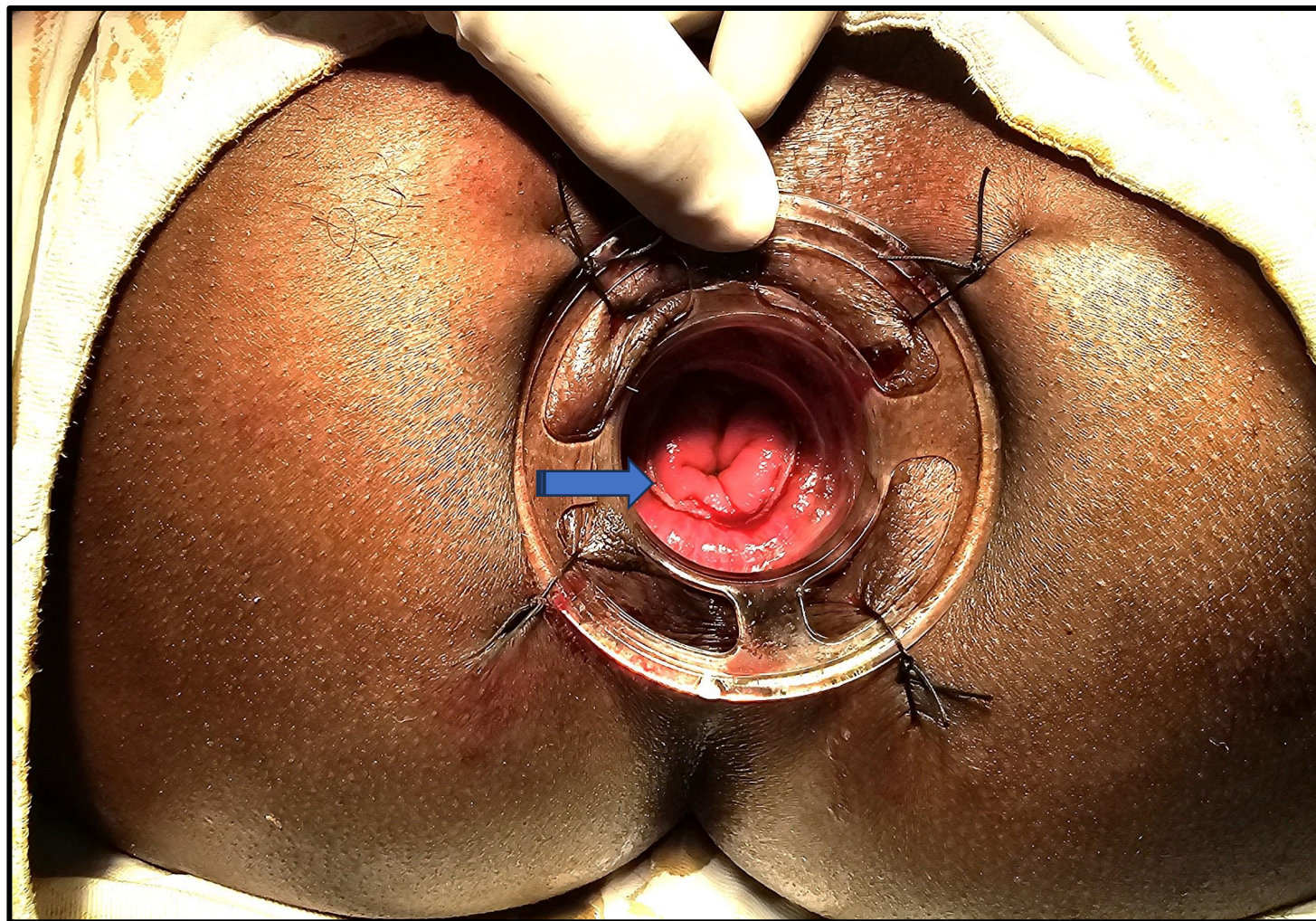




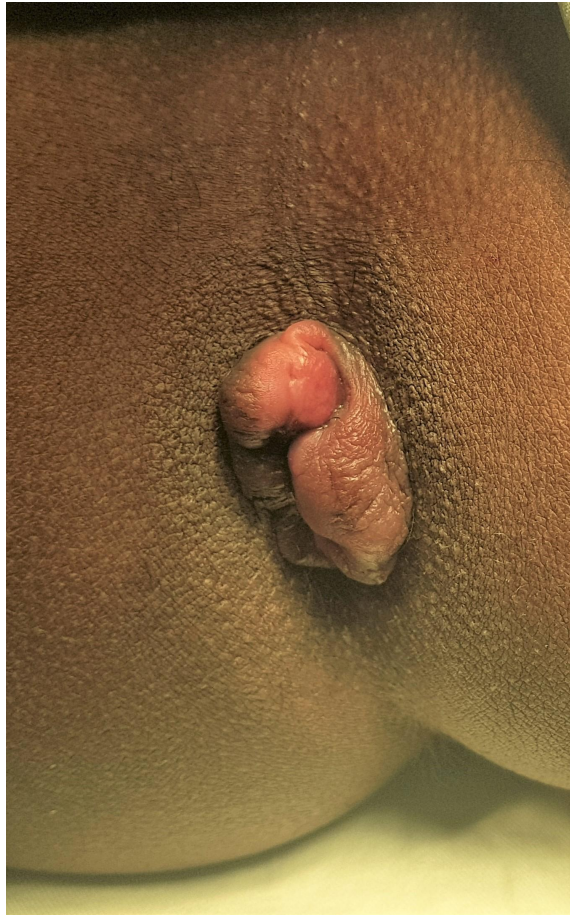Stapler dough nut



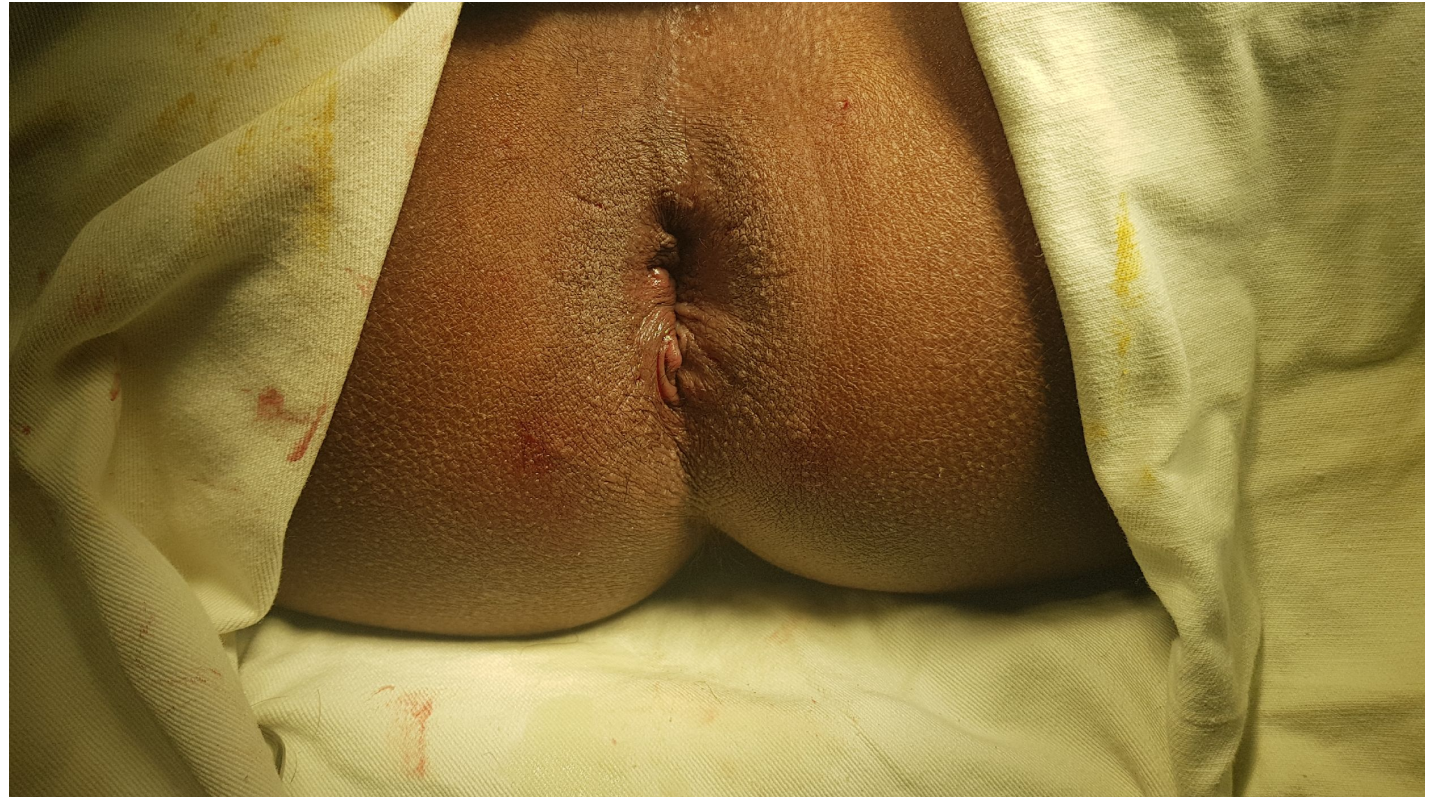Visible stapler line



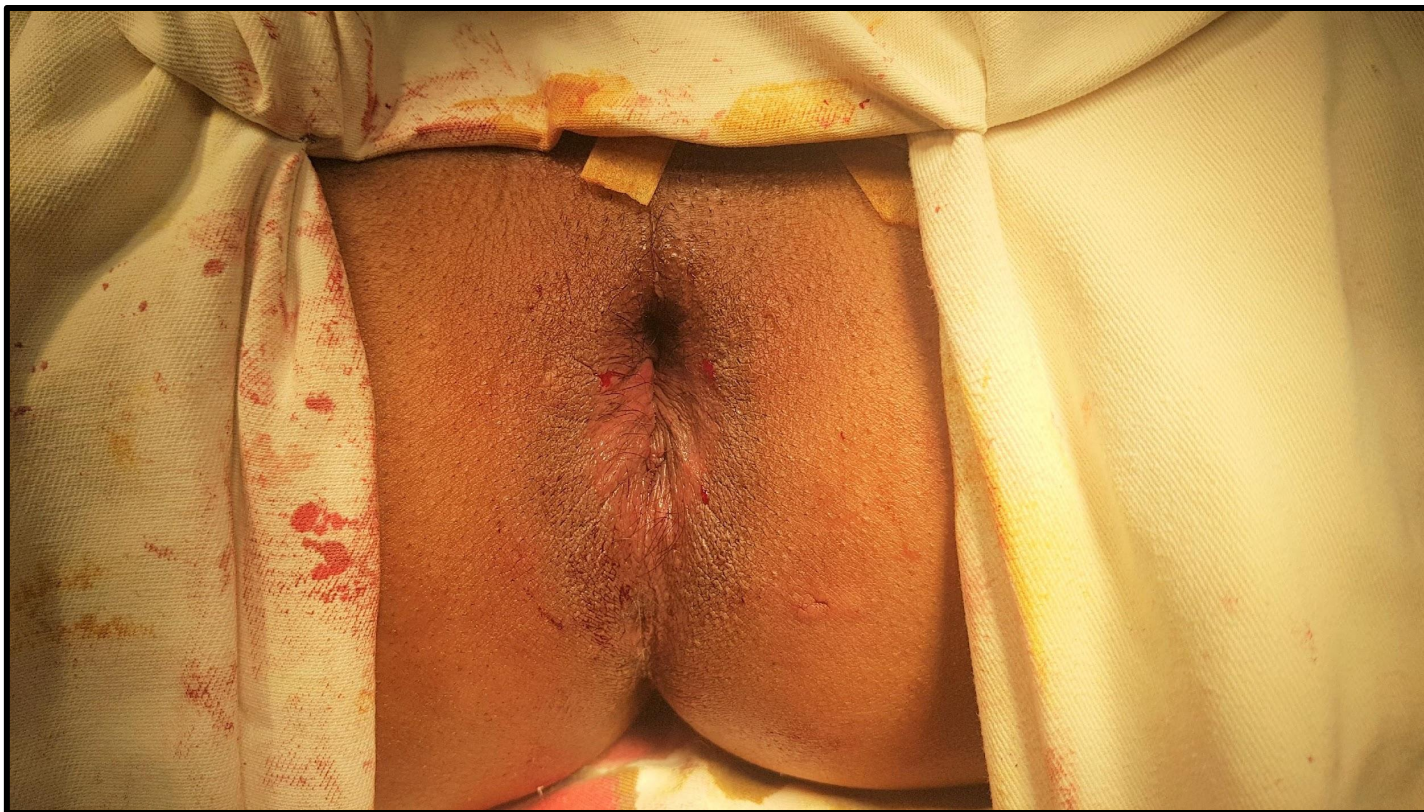Before Surgery



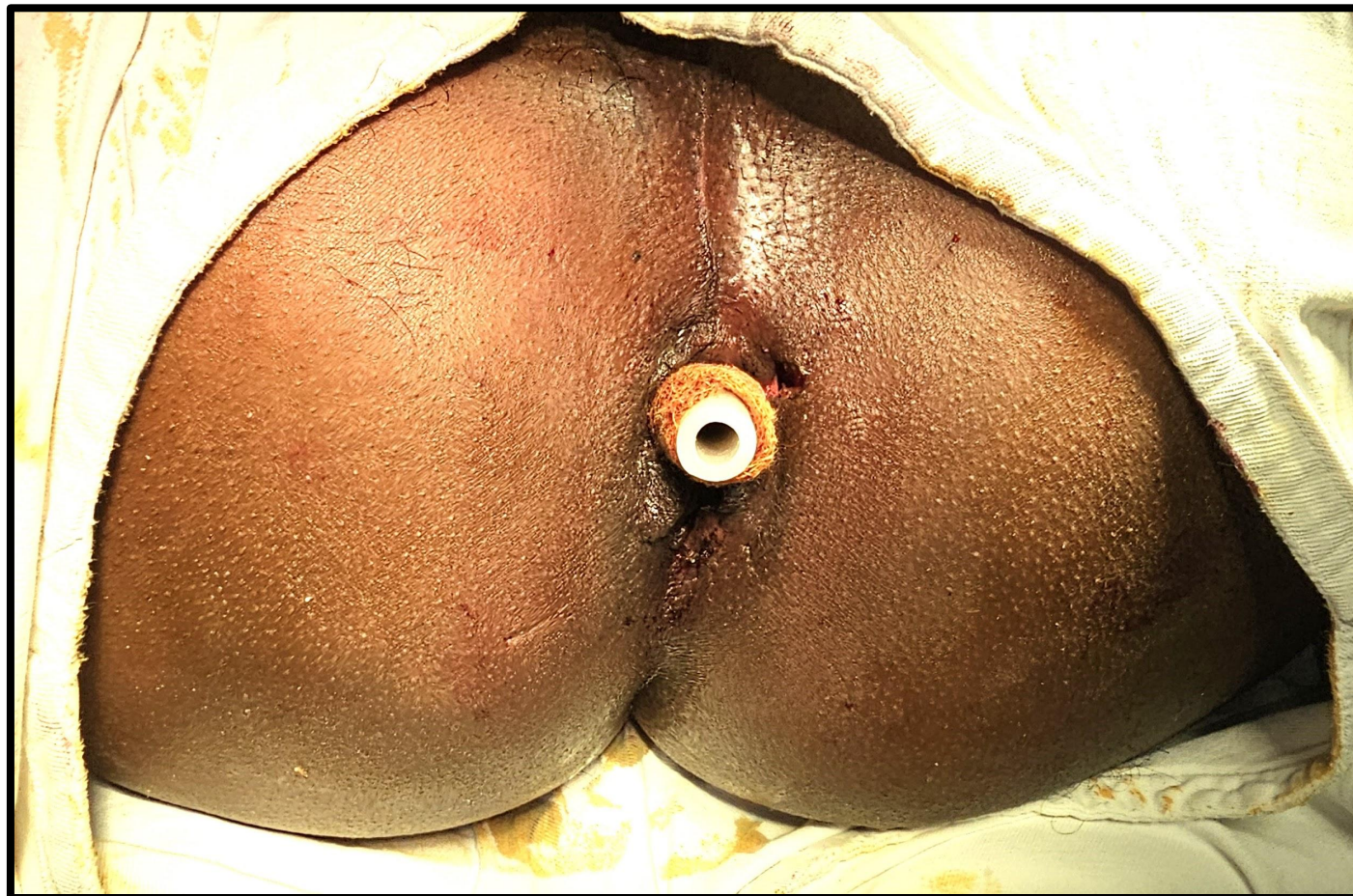
After Surgery

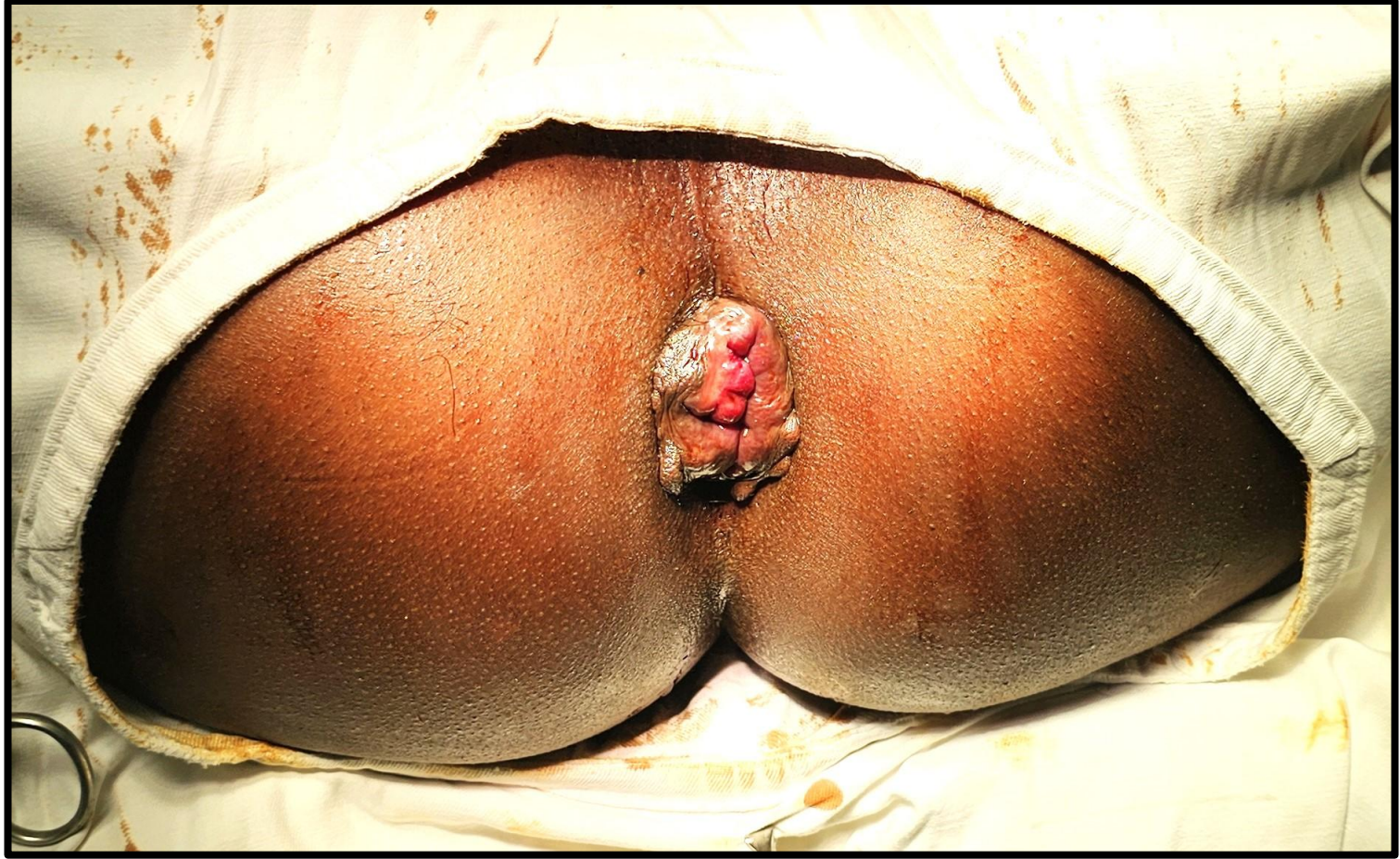

Final picture

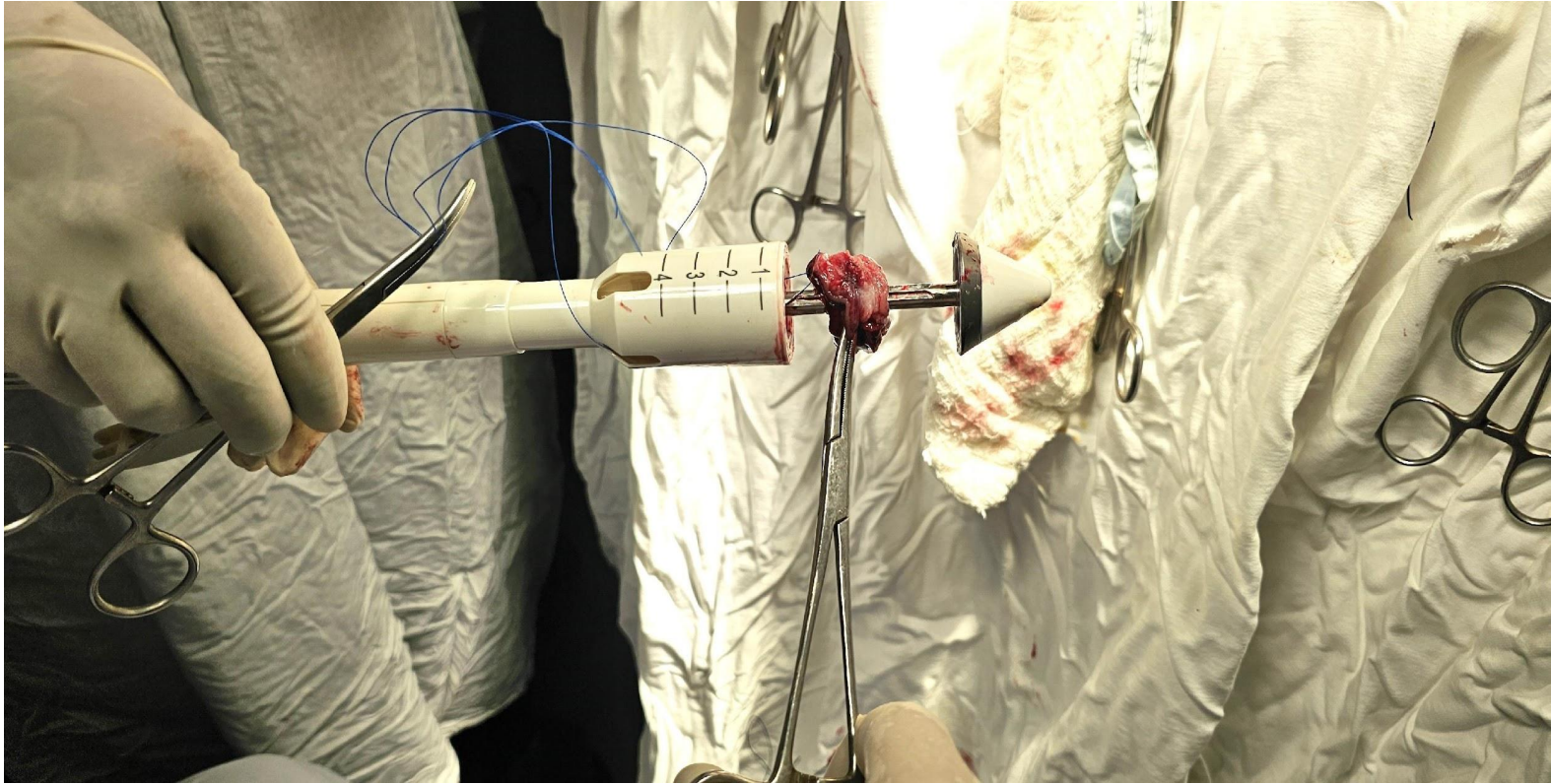
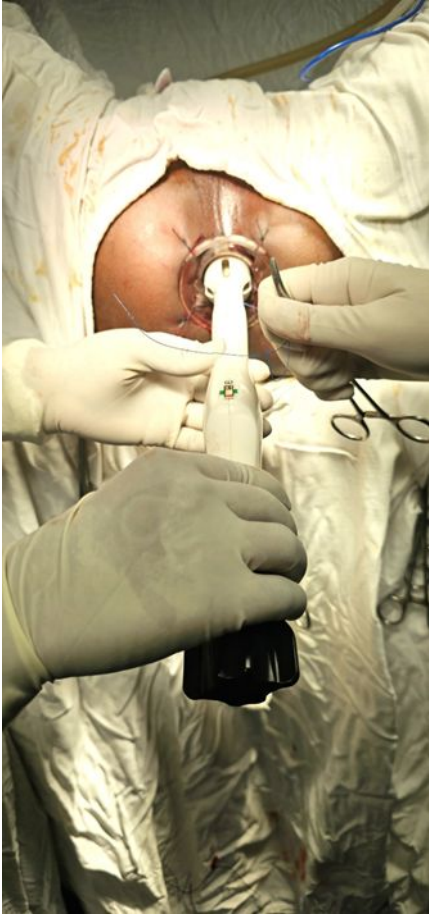

Flatus tube inserted

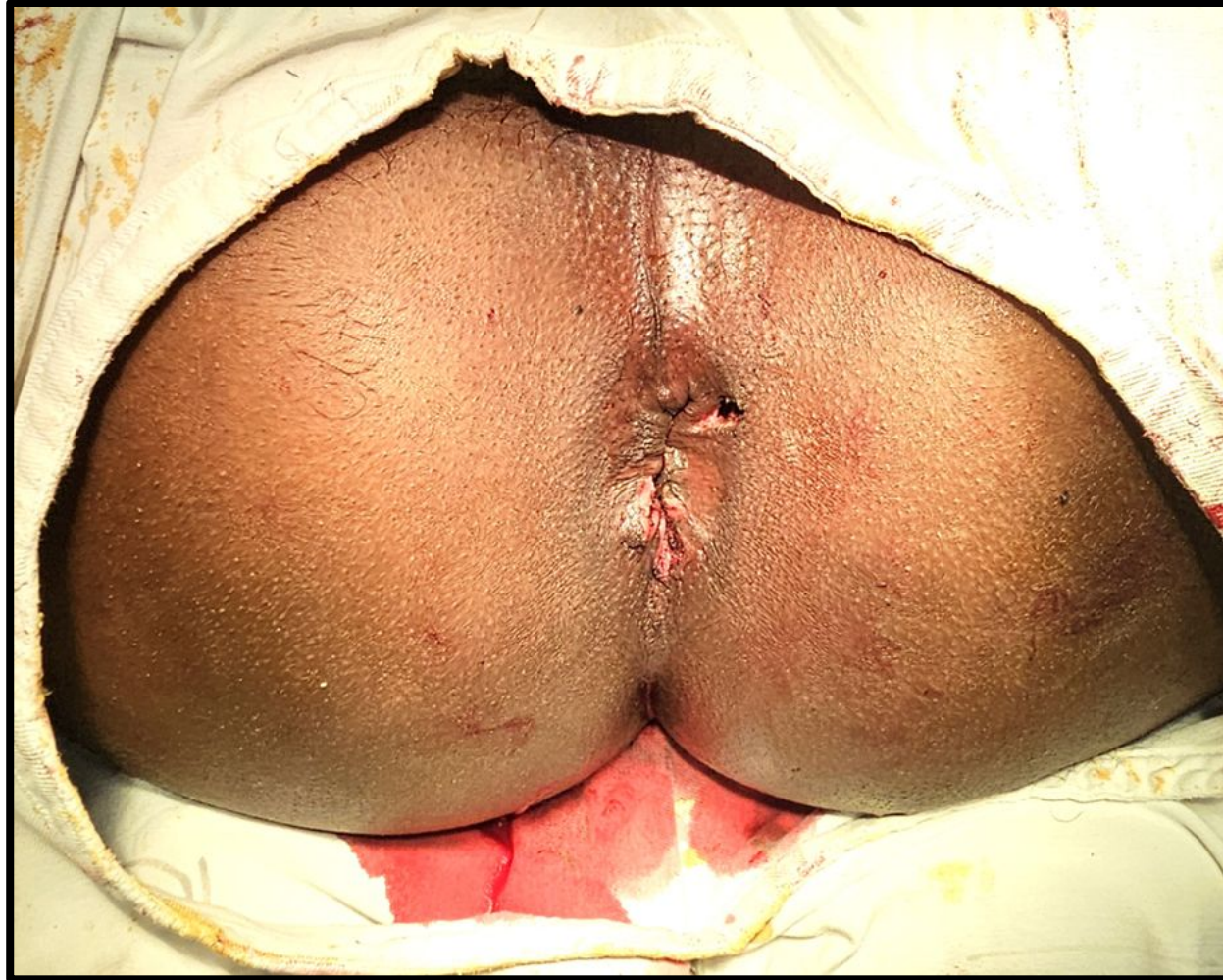



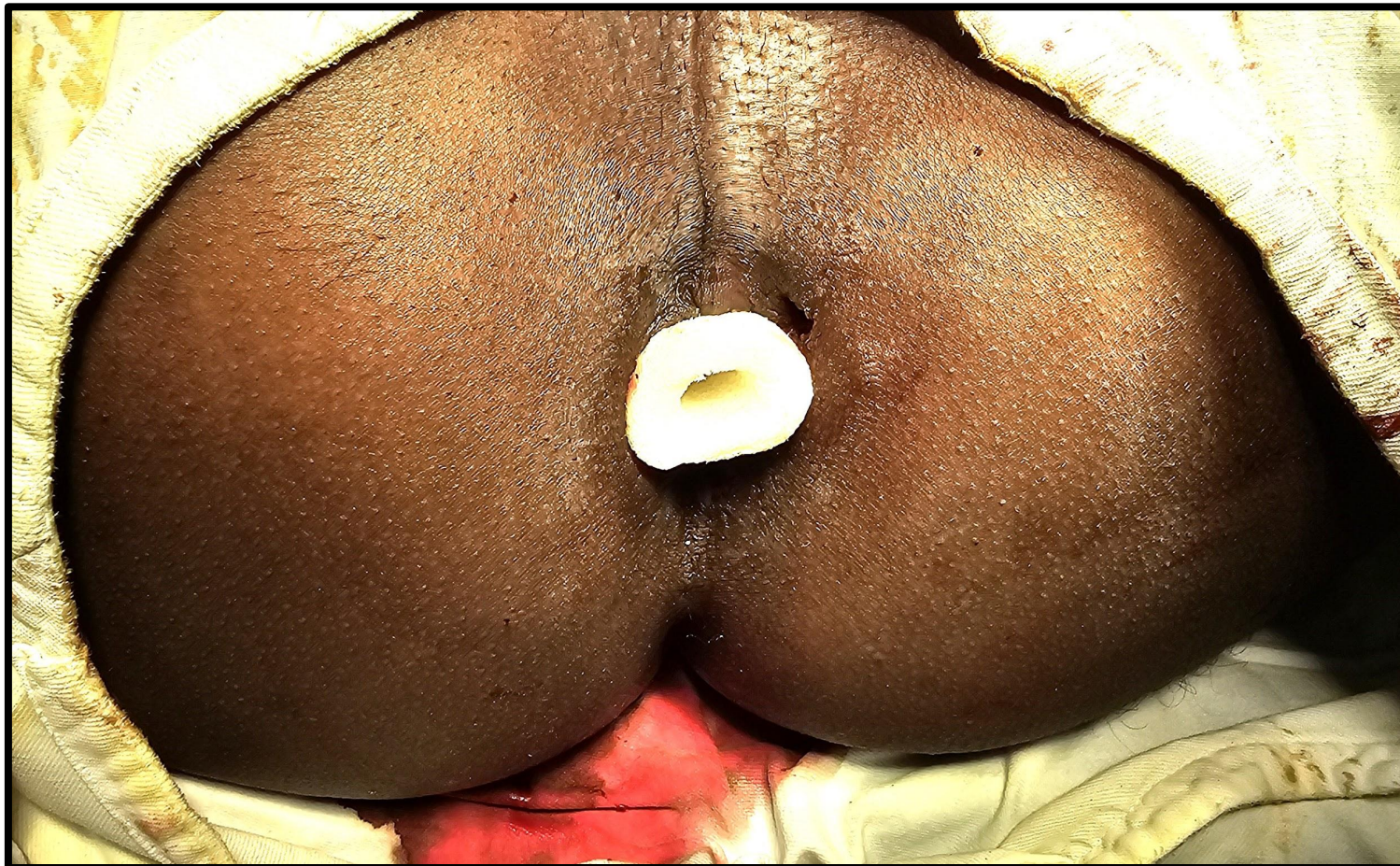Stapler gun 36 mm size



Post operative picture



Hemo-sponge inserted



Advantage of Longo operation

- No bleeding
- No open wound
- No pain
- No infection
- Early return to work
- Almost no recurrence
- Correction of mild to moderate degree ODS.
- Patient's satisfaction is high.

Study period from Dec 2013 to Dec 2023 in 3 hospitals(JIMC<Imperial Hospital CTG<AWMC)

- Total 1861 patients
- Age-12 years to 91 years
- Recurrence-3(0.16%)
- Anal stenosis-5(0.26%)
- Re-operation - Needed for 3(0.16%) patients with Milligan Morgan open technique.

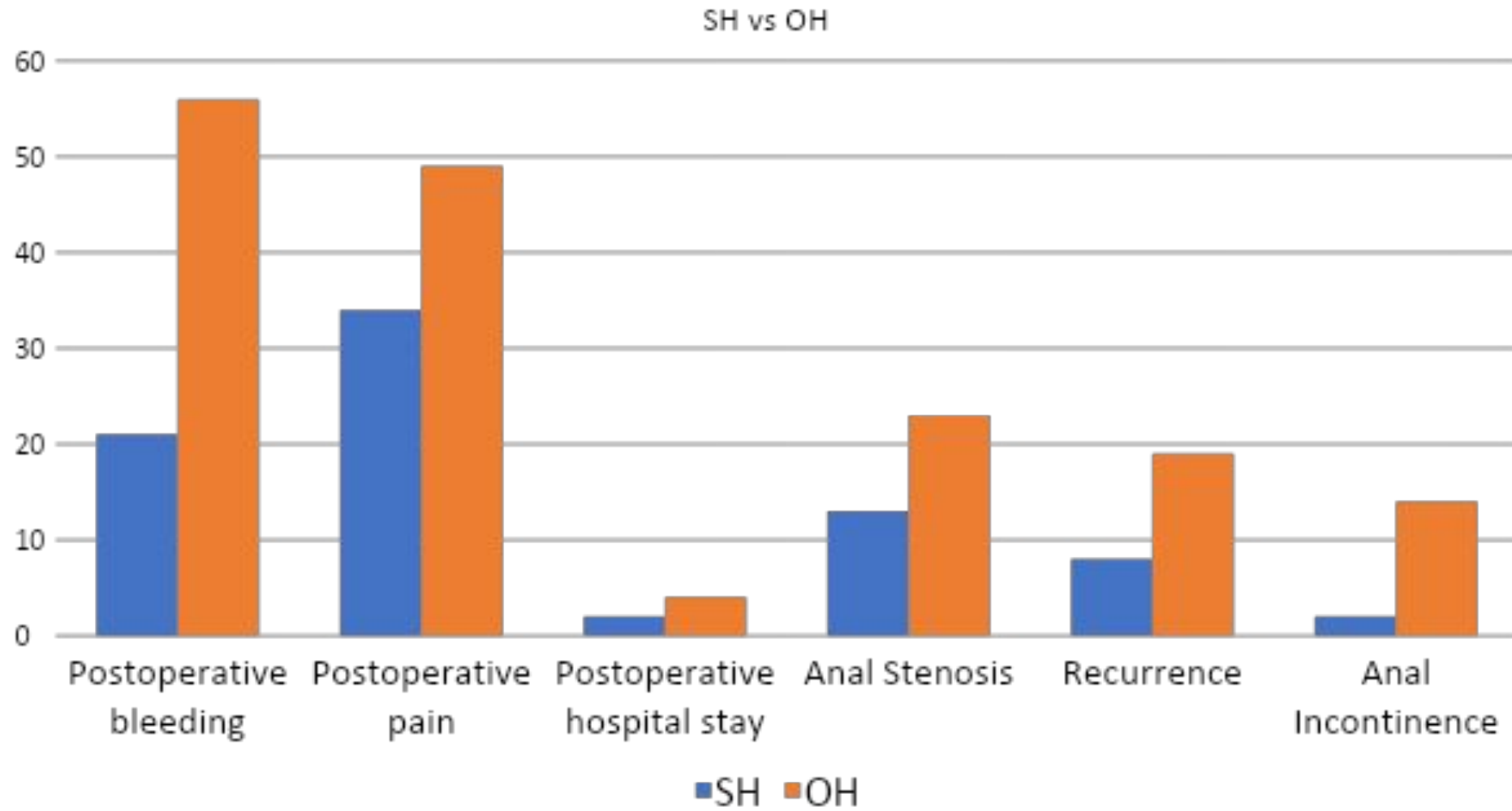
Study in BSMMU(Colorectal Department) From 2012-2022

- Total patients- 3476
- Open hemorrhoidectomy(OH) done for—1033.
- Stapped hemorrhoidopexy(SH) done for- 2443.
- Follow up done: After 2 weeks
 - After 1 month
 - After 3 months

SH vs OH

Evaluating points	Stapled hemorrhoidopexy(SH) -2443	Open hemorrhoidectomy(OH)- 1033
Postoperative bleeding	21 (0.85%)	56 (5.42%)
Postoperative pain	34 (1.39%)	49 (4.74%)
Postoperative hospital stay	1-2 days	3-4 days
Anal Stenosis	13 (0.53%)	23 (2.22%)
Recurrence	8 (0.32%)	19 (1.83%)
Anal Incontinence	2 (0.08%)	14 (1.35%)

SH vs OH





Research Article

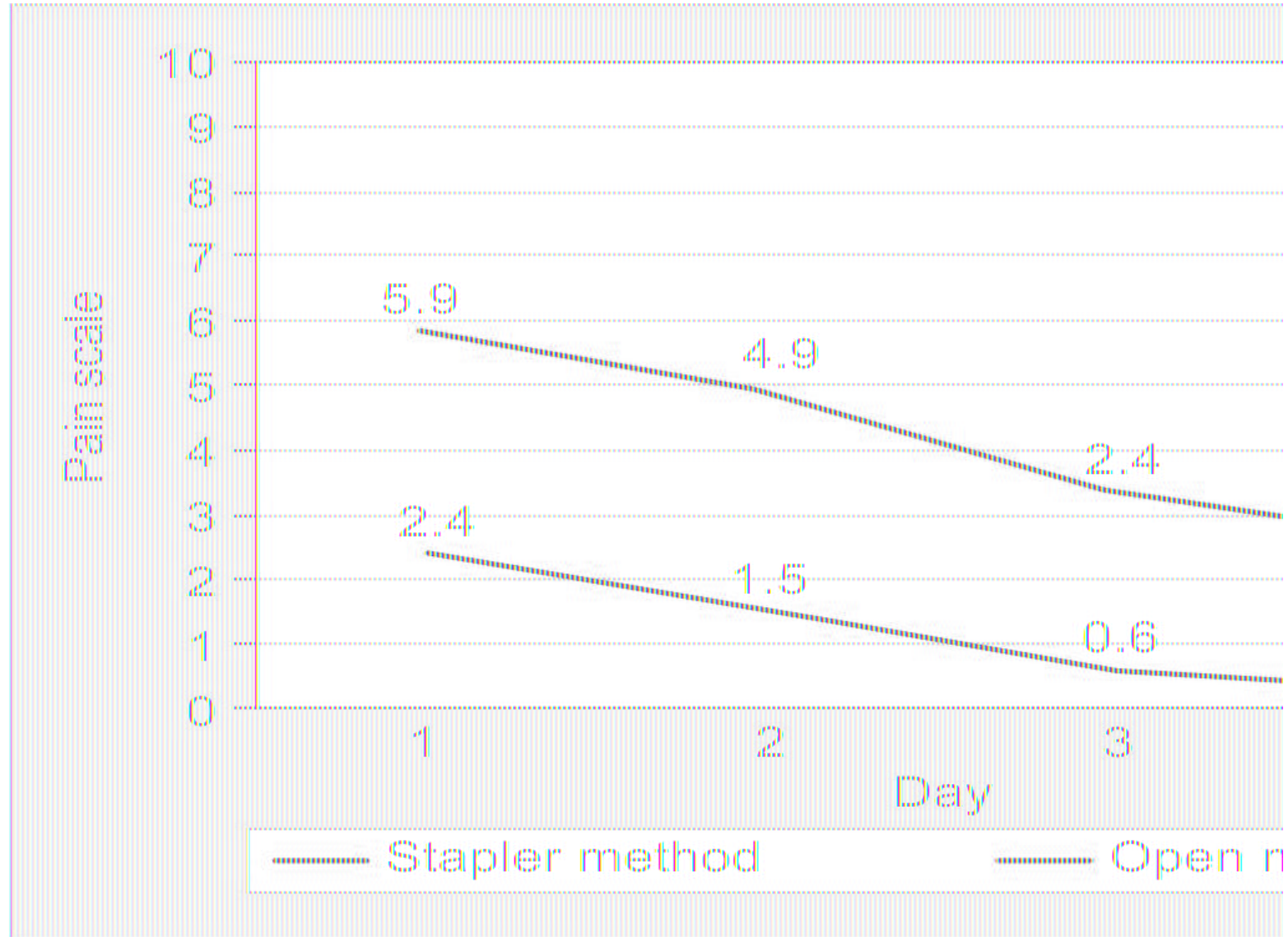
**A Prospective Comparative Study of Stapler Hemorrhoidectomy Vs
Open Haemorrhoidectomy (Milligan Morgan) in its Outcome and
Postoperative Complications**

Dr. Nambula Malyadri^{1,*}, Dr. Veera Jayachandra Allu²

SH vs OH

	Stapler haemorrhoidopexy (N=40)	Open hemorrhoidectomy (N=40)	P Value
Post-operative bleeding(ml) Median (IQR)	2(1 to 2)	12 (10 to 14)	<001*
Post-operative pain- VAS score Median (IQR)	3(3 to 4)	5 (5 to 6)	<0001*
Post-operative Hospital stay in days Median (IQR)	1(1 to 1)	3 (3 to 3)	<0001*
Recurrence	2 (5%)	1(2.5%)	0.556
Incontinence	0 (0%)	3 (7.5%)	**
Anal stenosis	0 (0%)	2 (5%)	**

Pain score SH vs OH



Conclusion

- Since the introduction of Stapled hemorrhoidopexy, the procedure has rapidly gained its place throughout the world.
- The technique is effective, and its immediate tolerance has been clearly demonstrated comparison to open hemorrhoidectomy.
- Considering the widespread acceptance of Stapled hemorrhoidopexy, it is time to acknowledge it as the 'Gold Standard Treatment for Hemorrhoid'.

A rustic, handmade-style tag made of brown cardboard or paper, featuring the words "Thank you!" written in a black, cursive script. The tag is placed on a light-colored wooden surface with a visible grain. To the right of the tag is a single white daisy with a bright yellow center. In the background, two more daisies are visible, slightly out of focus. A dark, thin cord or string is visible on the left side of the tag, passing through a small hole. The overall scene is warm and natural, suggesting a thoughtful, handmade gift or note.

Thank
you!