

# Premature rupture of membrane

PRESENTED BY

**DR. IRIN AKTER**

**MBBS, DGO (IN COURSE)**

**DEPT. OF OBSTETRICS & GYNAECOLOGY**

**AD-DIN WOMEN'S MEDICAL COLLEGE  
AND HOSPITAL**

# case presentation

My patient, Mrs Fatema, 23 years old, primi gravida, housewife of low socioeconomic condition, hailing from Chadpur got herself admitted in this hospital on 04.01.2024 with the complaints of-

1. Pregnancy for 33 weeks.
2. Sudden gush of per vaginal watery discharge for 1 day.

- ▶ According to the statement of the patient she was a regularly menstruating woman with average flow and duration. Her LMP was on 16.05.23 and accordingly EDD will be on 23.02.24. She was on regular antenatal check up and duly immunized against tetanus. Her pregnancy was uneventful before 33 weeks.

1 day ago she noticed sudden gush of per vaginal watery discharge which was moderate in amount, clear and non-odorous.



The amount of leakage was increased on walking and change of posture.

Now it is decreasing. The discharge is not associated with lower abdominal pain, fever and vulvo vaginal itching. She had no complaints of any urinary problem like urgency, frequency, dysuria and incontinence.

With this complaints she is admitted in this hospital for better management

- ▶ Regarding her obstetrical history she is married for 3 years. Before this conception the couple practiced barrier method of conception.
- ▶ Regarding her personal history she is normotensive, non diabetic, non-smoker and non-alcoholic.
- ▶ With due consent and maintaining adequate privacy I examined her and  
found her anxious but co-operative with average bodybuilt. Her pulse was  
88 bpm, BP-120/80 mmHg, temperature-98.4 F. She is mildly anaemic,  
non icteric and oedema is absent.



Regarding per abdominal examination- Uterus is uniformly enlarged, umbilicus is centrally placed ,linea nigra and striae gravidarum are present.

On palpation uterus is soft,relaxed and non tender.SFH is 29cm and abdominal girth is 82cm.There is a single fetus with longitudinal lie with cephalic presentation.

Fetal parts are easily felt . Fetal heart rate is regular and 144 bpm.

▶ Regarding per vaginal examination:

On inspection-Vulval pad is soaked with watery discharge which was not associated with foulsmelling.

On gentle speculum examination-Watery fluid was coming out through external os while coughing.Cervical os is closed. There is no evidence of cord prolapse.

# PROVISIONAL DIAGNOSIS

- ▶ A CASE OF PRIMI GRAVIDA WITH 33WEEKS PREGNANCY WITH PRE TERM PROM



# DIFFERENTIAL DIAGNOSOS

1. Hydrorrhoea gravidarum.
2. Urinary incontinence.

# INVESTIGATIONS

## ▶ USG of pregnancy profile:

AFI-6.2cm

EFW-2020gm

Placental location-Posterior fundal.

FHR-144bpm

Presentation-cephalic

Biophysical profile score-8/8

Impression:32 weeks of single alive intrauterine fetus with moderate oligohydramnios.

- ▶ CBC-Hb%-10.3 gm/dl  
ESR-25mm  
WBC-14,580/UL.
- ▶ CRP-17.12mg/dl
- ▶ FBS-4.6mmol/L and 2HABFS-6.8mmol/L.
- ▶ Urine routine examination- Pus cell :8-10/HPF  
color-straw  
appearance-clear
- ▶ Urine for culture and sensitivity-shows no growth of organism.

High vaginal swab for culture and sensitivity-

Shows no growth of organism.

# CONFIRM DIAGNOSIS

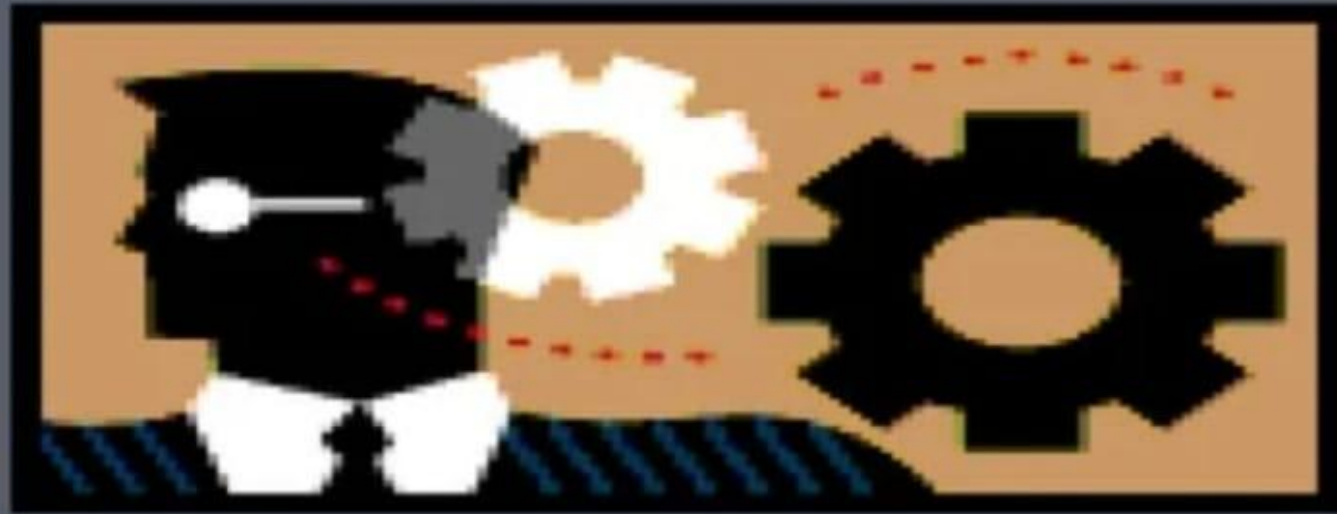From history taking, examination and some investigations my confirm diagnosis is-

- ▶ A case of **Primi gravida with 33 weeks of pregnancy with PRE-TERM PROM with moderate oligohydramnios with UTI**

# TREATMENT

- ▶ Complete bed rest.  
Antibiotics-Amoxicillin  
Erythromycin
- Steroid -inj.Dexamethasone
- ▶ Use sterile vulval pad.
- ▶ Monitor vital signs and fetal heart rate strictly.

# WHAT IS ??



PREMATURE RUPTURE  
OF  
MEMBRANE

# definition

- ▶ The spontaneous rupture of the fetal membranes any time beyond the 24 weeks of pregnancy but before the onset of labour.
  - After 37 weeks –Term PROM
  - Before 37 weeks –Preterm PROM



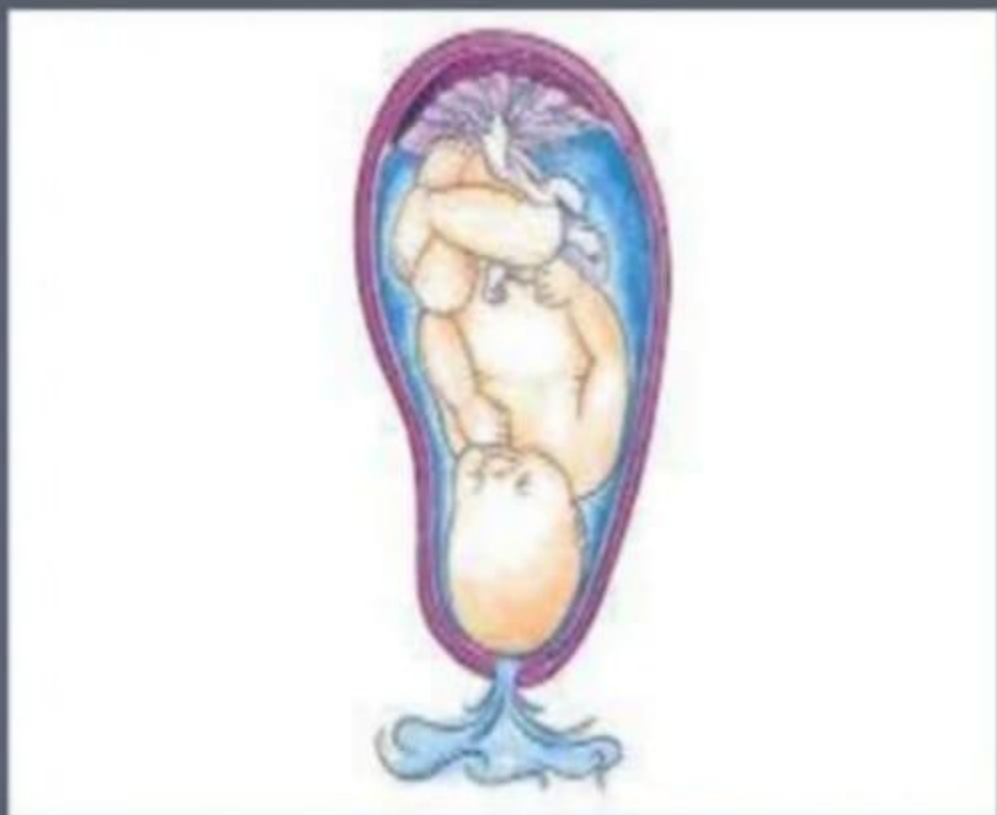
# Incidence

PROM-10%

# Pathophysiology

1. Increased friability

2. Reduced tensile strength



**PRE MATURE RUPTURE**  
**OF**  
**MEMBRANE**

# Risk Factors

1. Genital tract infection
2. UTI
3. Cervical incompetence
4. Polyhydramnios
5. Multiple pregnancy
6. Smoking
7. Low socioeconomic condition
8. Nutritional deficiency

# Diagnosis

## History

The only subjective symptom is escape of watery discharge per vagina either in the form of a gush or slow leak. There may be lower abdominal pain.

Examinations and Investigations are done to confirm diagnosis.

General examination- Anaemia, rise of temperature, tachycardia

Per abdominal examination- Tender abdomen

Decreased SFH

Decreased abdominal girth.

Fetal parts may be easily felt.

Altered fetal heart sound

## Speculum examination

Upon sterile speculum examination, ruptured membrane is diagnosed if

- . Amniotic fluid pools in the posterior fornix and
- . If clear fluid flows from the cervical canal

# Investigations

## Nitrazine paper testing

- Turns blue in the presence of alkaline amniotic fluid
- 93.3% sensitivity
- False positive in (1-17%) cases

# Ferning Pattern

- .Microscopic ferning pattern of the amniotic fluid when drying on slide
- .Amniotic fluid crystalizes to form a fern like pattern due to its relative concentrations of sodium chloride, proteins, and carbohydrates

## Nile blue test

- . When centrifuged cells stained with 0.1% Nile blue sulphate- There is orange blue coloration of the cells

# Amnisure

- .Detects PAMG-1 (placental macroglobulin)

- .99% sensitivity, 100% specificity

- .PAMG-1 is a protein produced by cells of decidual part of placenta and can be detected in amniotic fluid after rupture of membrane.



# Ultrasonography

- .50-70% women with PROM have low amniotic fluid on USG.
- .Mild reduction requires further investigation.

## Indigo carmine dye test

- .Amniocentesis with injection of dilute solution of indigo carmine dye is done.PROM is confirmed if vaginal pads are soaked with blue dye after 15-30 minutes

High vaginal swab culture-May  
show growth of organism

Urine routine analysis and  
culture-May show growth of organism

Complete blood count

CRP

Cardiotocography for non stress  
test

.


# Complications

## Maternal

- Preterm labour
- Chorioamnionitis
- Abruptio placenta
- Dry labour
- PPH
- Increase operative interference
- Puerperal sepsis

## FETAL

- Prematurity
- Fetal pulmonary hypoplasia
- Cord compression
- Fetal distress
- Neonatal sepsis
- RDS



Intraventricular haemorrhage  
Necrotizing enterocolitis  
Fetal death  
Perinatal morbidities

# Chorioamninitis is diagnosed if

- .Fever
- .Uterine tenderness
- .Offensive vaginal discharge
- .Fetal or maternal tachycardia
- .Leucocytosis(>15000 cells/mm<sup>3</sup>)
- .C reactive protein > 2.7 mg/dl

In case of chorioamnionitis-Termination of pregnancy irrespective of gestational age (short trial for vaginal delivery, if fails then caesarean section).

# Management of PROM

Pregnancy >24-<33 weeks : Expectant management.

- .Hospitalization

- .Antibiotics

- .Steroids administration

- .Tocolytics if there is uterine contraction on admission to  
to get benefits of steroid administration

- .Maternal and fetal monitoring



Pregnancy >34-<36 weeks

.Antibiotics

.Corticosteroid course

.To wait for spontaneous onset of labour for 24-48 hours

.If fails then induction of labour with oxytocin

Pregnancy >37 weeks

.To wait for spontaneous onset for labor for 24 hours

.If fails then induction of labour with oxytocin

**THANK YOU**